

# ***LIBYAN JOURNAL OF DENTISTRY***



**VOL3, NO 1**

**MARCH 2019**



***[www.ljduob.wordpress.com](http://www.ljduob.wordpress.com)***

## ***Citation***

***Bushaala HM, Yasear AY, Sultan AA, Khatal AA.. Effect of Pilocarpine on Minor Salivary Glands of Rabbits: A Histological Study. Libyan Journal of Dentistry. 2019; 3(1):1-10***

### Original Article

# Effect of Pilocarpine on Minor Salivary Glands of Rabbits: A Histological Study

Hamida .M. Bushaala<sup>a</sup> , Akram .Y. Yasear<sup>b</sup> , Azzam .A. Sultan<sup>a</sup> , Abdelraouf .A. Khatal<sup>b</sup>

<sup>a</sup> Faculty of Dentistry, Department of Oral Biology, Department of Oral Medicine, Oral Pathology, University of Benghazi, Libya.

<sup>b</sup> College of Dentistry, University of Kerbala, Iraq.

## ABSTRACT

**Back ground:** Pilocarpine is a parasympathomimetic agent with mild  $\beta$ -adrenergic increase the rate of salivation. It is commonly used for treatment of patients with Sjögren's syndrome and post radiation salivary gland hypofunction. The intention of the present work was to describe the effects of Pilocarpine drug which is used as a drug with parasympathomimetic effect and the histological changes during treatment with it. **Methods:** Eighteen male rabbits were used in this experiment to show the effect of Pilocarpine. Different doses of drug 3mg/kg and 5mg/kg were given to treated groups (A and B) within the therapeutic limits. The experimental animals were injected intraperitoneally twice daily, for two and six weeks. Samples of the minor salivary glands were processed for light microscopy. Sections of the minor salivary glands were stained with H&E and PAS stains. Statistical analysis was followed to measure the diameter of the secretory acini. **Results:** The most noticeable changes were significant increase in the diameter of the secretory acini, and vacuolation with foamy appearance of the cells of the acini in treated groups. The PAS positive reaction in the acini was increased as the dose of the drug increased. **Conclusion:** Pilocarpine as sialogogue drug simulates the effect of parasympathomimetic drugs. The structural histological alterations noticed in this study substantiate the use of Pilocarpine as prophylactic and therapeutic agents in patients suffering from xerostomia, patients receiving radiotherapy at head and neck malignancies, and some diseases like Sjögren's syndrome.

**Key words:** Rabbits, minorsalivary glands, histology, Pilocarpine, vacuolation.

### Corresponding author :

Hamida .M. Bushaala

Faculty of Dentistry, Department of Oral Biology, Department of Oral Medicine, Oral Pathology, University of Benghazi, Libya.  
E mail: bushaalah@yahoo.com

## INTRODUCTION

Saliva is produced in and secreted from salivary glands<sup>(1)</sup>. Saliva is rich in mechanisms and functions that are important, not only for oral health, but also for general health and well-being<sup>(2)</sup>.

Whole mouth saliva also contains small amounts of other fluids and products of the mucosal surface, this complex fluid has digestive, lubricating, and protective functions<sup>(3)</sup>. In humans, there are three pairs of large salivary glands (parotid, submandibular, and sublingual glands). In addition, 600-1000 minor salivary glands line the oral cavity and oropharynx, contributing a small portion of total salivary production, these glands secrete 10% of the total volume of saliva, but they account for approximately 70 % of the mucus secreted<sup>(4,5)</sup>.

Dry mouth can seriously impair oral health and diminish the quality of life<sup>(6)</sup>. Patients with xerostomia and hyposalivation generally deal with palliative treatment for the relief of symptoms and prevention of oral complications<sup>(7)</sup>.

Oral Pilocarpine is the primary drug used in the management of xerostomia, particularly those exposed to radiotherapy, in Sjögren's syndrome and graft-versus-host disease<sup>(8)</sup>. Pilocarpine is a parasympathomimetic agent with mild  $\beta$ -adrenergic stimulating properties, it can significantly improve symptoms of dry mouth and increase salivary output<sup>(9)</sup>.

The present study was undertaken to investigate the participation of Pilocarpine drug in the histological structural changes in rabbit minor salivary glands.

## MATERIALS AND METHODS

**Experimental animals:** The present experiment was conducted on eighteen healthy male rabbits, 4-5 months old, of local mixed breed, weighing between 1.5 – 2.5 kg, they were kept under controlled laboratory conditions for two weeks for acclimatization of animals to the laboratory

environment. The animals were allowed unrestricted access to food and water. According to the dosage of the drug used, and the duration of administration of the drug, the rabbits were divided into four groups (A, B, C and D). Each group was further subdivided into two subgroups according to duration of administration of the drug and saline.

**Drug used:** Pilocarpine HCL was used for groups (A and B). It is a cholinergic agonist (parasympathomimetic) agent. This drug was available as sterile eye drops, each 1ml contains 20 mg of Pilocarpine HCL. Drug was stored at room temperature and protected from light. Benzalkonium chloride (0.2 mg) which is present as preservative in the drug. This preservative was given to group (C), and it was used in this study to determine if it had any effect on minor salivary glands or not. Saline was used as placebo for control group (D).

**Calculation of the drug dose:** The drug dose used in this experiment was calculated according to Pagat and Barnas formula (1964) <sup>(10)</sup>. Human dose of Pilocarpine is 20 mg twice a day. According to this formula, the dose for rabbit weighing 2 kg =  $20 \times 0.07 = 1.4 \times 2 = 2.8$ . So the therapeutic dose used in this study was 3mg of Pilocarpine twice a day. Beside using a double dose of approximately 5 mg of the drug.

**Methods:** The present study was conducted on 18 male rabbits; the experimental animals were injected intraperitoneally twice daily for each group and divided into the following groups:

**Group -A** includes 6 rabbits. They were given the drug twice daily. This group was divided into sub-groups:

- 1- Group<sub>a1</sub> 3 rabbits were given 3 mg/kg Pilocarpine <for 2weeks>.
- 2- Group<sub>a2</sub> 3 rabbits were given 3mg/kg Pilocarpine <for 6 weeks>.

Specimens were taken immediately at the end of the experiment period from the minor salivary glands (Weber's, buccal and soft palatine glands).

**Group -B** includes 6 rabbits. They were given the drug twice daily. This group was divided into the following sub-groups:

1. Group<sub>b1</sub> 3 rabbits were given 5mg/kg Pilocarpine <for 2 weeks>.
2. Group<sub>b2</sub> 3 rabbits were given 5mg/kg Pilocarpine <for 6 weeks>.

Specimens were taken immediately at the end of the experiment period from the minor salivary glands (Weber's, buccal and soft palatine glands).

**Group -C** includes 2 rabbits. They were given the preservative <benzalkonium chloride 0.2mg> twice daily. This group was divided into the following sub-groups:

1. Group<sub>c1</sub> 1 rabbit was given benzalkonium chloride <for 2 weeks>.
2. Group<sub>c2</sub> 1 rabbit was given benzalkonium chloride <for 6 weeks>.

Specimens were taken after that from the minor salivary glands (Weber's, buccal and soft palatine glands).

**Group -D** includes 4 rabbits serves as a control and were given saline injection to simulates the effect of injection. This group was divided into the following sub-groups:

- 1- Group<sub>d1</sub> 2 rabbits were given saline <for 2 weeks>.
  - 2- Group<sub>d2</sub> 2 rabbits were given saline <for 6 weeks>.
- Specimens were taken after that from the minor salivary glands (Weber's, buccal and soft palatine glands).

The collected samples of the minor salivary glands, included in this study, were ran through paraffin embedding technique to get paraffin blocks. Histological serial sections were cut from the minor salivary gland of each group. Serial sections 5 µm thickness were cut and mounted on glass slide.

**Stains:** 1-Hematoxylin and eosin (H and E) stains were used for general examination.

2- Periodic acid Schiff's (PAS) reaction was used as a general stain for presence of mucopolysaccharide substances.

**Statistical analyses:** Histometric evaluations of diameter of secretory end pieces were conducted on slides stained by hematoxylin and eosin stain. For the measurement we used Müller USB Microscope Camera with TUCSEN Digital Imaging Technique. The readings obtained randomly were in micrometer with scale 10.00. The number of readings were 144 readings, 18 for each group representing the glands included in the present study. Data was checked and fed to personal computer using statistical package for social sciences (SPSS) version 22 <sup>(11)</sup>. Descriptive statistics was used in the form of minimum, maximum, mean and standard deviation. To compare between the mean of diameters of salivary glands of different groups, Analysis of Variance (ANOVA) test was used. P value was considered significant if it is less than 0.05 and highly significant if P value is less than 0.01. To decide which group is different from other groups (ANOVA) a post HOC test was followed.

## RESULTS

**Clinical observation:** The following observations were noticed 20 minutes after injection in the rabbits of group A and B which were injected with therapeutic dose of Pilocarpine:

- Increase in activity of rabbits and they became more aggressive.
- Increase in body temperature.
- Increase in water consumption.
- Excessive salivation (drooling of saliva).

**Histological findings:** In sections stained with the H and E stain, the minor salivary glands in both treated and untreated groups were located beneath the epithelium in submucosa throughout most of oral cavity. These glands were consisting of several small groups of secretory units, usually open via short ducts directly into the mouth cavity. They lack a distinct capsule, instead they were mixed with the connective tissue of the submucosa or muscle fibers of the tongue or cheek. The minor salivary glands secretory units in the rabbits of both control and treated groups were composed of mostly mucus acini. The most prominent feature of mucous cells was the accumulation in the apical cytoplasm of large amounts of secretory product (mucus), which compressed the nuclei towards the basal side of the cells, thus the nuclei appeared flattened. The secretory products, which were accumulated on the apical side of the cell, appears pale and poorly stained giving an empty appearance to the supranuclear cytoplasm (Figure 1).

**Histological effect of Pilocarpine:** In the treated groups (A and B), the most noticeable changes in the minor salivary glands were the vacuolation and foamy appearance of the cells of the secretory acini (Figure 2) and increasing size of acini with wide lumens (Figure 3). Other obvious change was an increase of the diameter of the acini in treated groups compared with acini in the control groups (Figure 4). The Weber's gland of treated groups was the most affected one by Pilocarpine treatment. The most obvious change was the increase in the diameters of acini that give the highest readings among them (Table 1). In treated groups (A and B) show transformations, spacing present between acini, increase in diameters and sizes of acini (Figure 5). The effect of the drug and its transformation was more obvious in group B with the increasing of the dose of the drug, than that occur in group A (Figure 7). This transformation and diameter increasing became more with time increasing. No difference was seen between preservative groups and control groups. The measurements of the diameters of

the acini of both groups were approaching each other (Table 3). Also there was no effect of used preservative on minor salivary glands.

For the PAS stained sections, positive reactions were identified in all groups of the minor salivary glands. The most obvious reaction obtained was in treated groups (A and B), there were abundant mucosubstance secretions (Figure 6).

The statistical analysis has revealed a change in the diameter of the acini of minor salivary glands (Table 3 and Figure 7). There was a difference between the treated and the control groups with P value = 0.000 (Table 2).

ANOVA test was applied on the diameters of salivary glands of the groups treated with Pilocarpine & control groups, and revealed a highly significance difference ( $<0.01$ ), this difference was in direct proportional to increase of Pilocarpine dose and duration of treatment (Table 4 and 5), but there was no significance and noticeable difference between preservative groups and control groups, with P value = 0.227 in 2 week and P value = 0.172 in 6 week (Table 4 and 5).

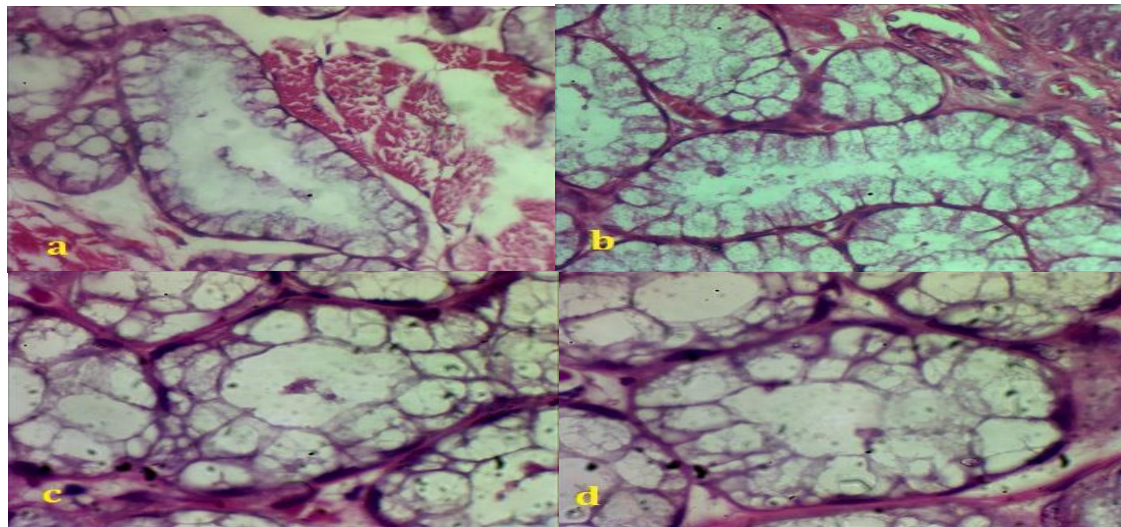
## DISCUSSION

This study has demonstrated the correlation between the histological changes of the minor salivary glands and clinical observations of the rabbits response to different dosages of Pilocarpine drug for two different periods followed in the present work.

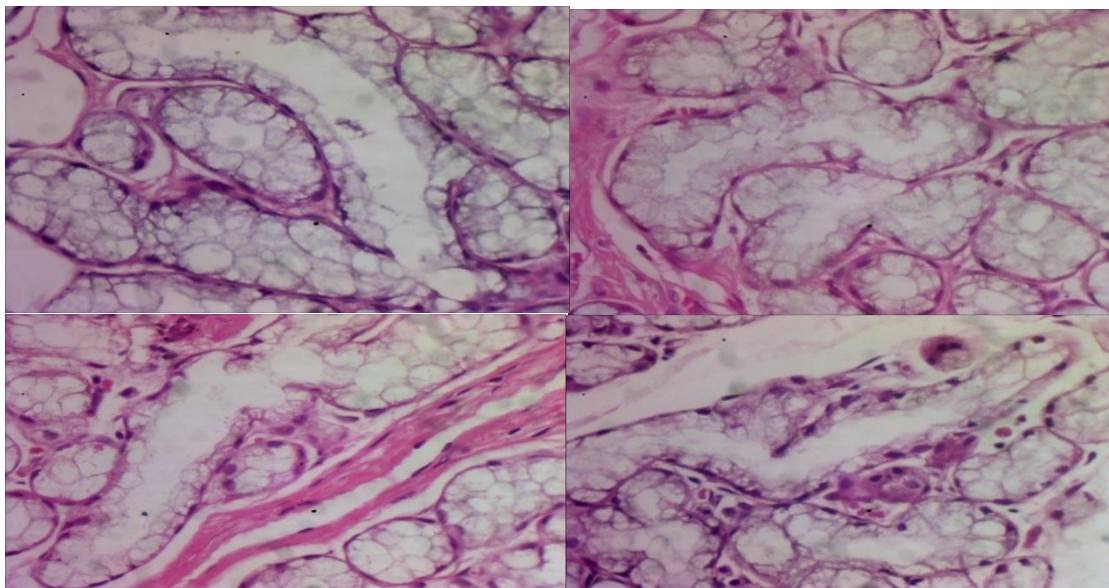
The minor salivary glands have displayed more sensitivity to Pilocarpine, this is confirmed in a previous study performed on Sjögren's syndrome patients, demonstrated a significant increase in labial salivary gland flow, as well as whole salivary flow as stimulated by Pilocarpine drug <sup>(12)</sup>. In a preceding study, the findings illustrated the greater resistance and recoverability of the mucous secreting minor palatal glands in contrast with the serous secreting parotid glands. They also showed the significant post radiation ability of the mucous secreting glands to be stimulated by Pilocarpine <sup>(13)</sup>. Study of Horiot et al showed that oral Pilocarpine acts primarily by stimulating minor salivary glands and can be of benefit to patients suffering of severe xerostomia regardless of radiotherapy dose/volume parameters <sup>(14)</sup>.

The literature clearly demonstrates that Pilocarpine evokes constituents of saliva such as mucins, proteins, glycoproteins, and electrolytes, with recognized increases in salivary amylase, protein-bound, carbohydrate, lysozyme, total protein, and calcium after Pilocarpine stimulation in normal subjects <sup>(15)</sup>.



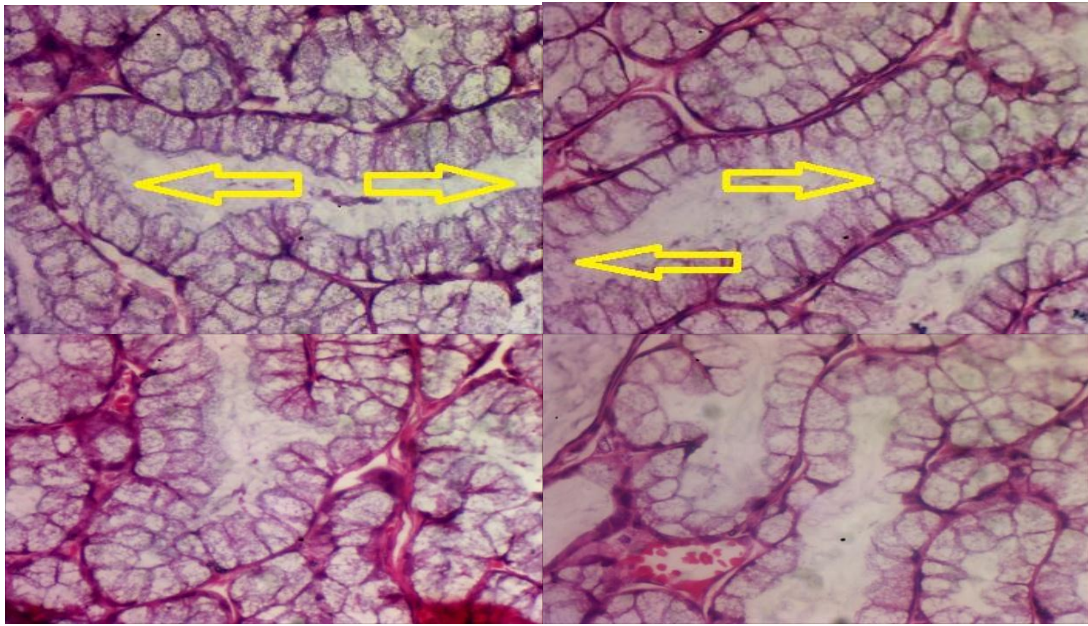


**Figure 1:** Photomicrographs of the minor salivary glands: < in picture (a) soft palatine gland in group b1, in picture (b) weber gland in group b1, in pictures (c, d) buccal gland in group a2 > showing pale staining tubuloacinar mucous cells giving an empty appearance to the supranuclear cytoplasm. Hematoxylin and eosin (H&E) stain. X400 (a, b) and X1000(c, d).

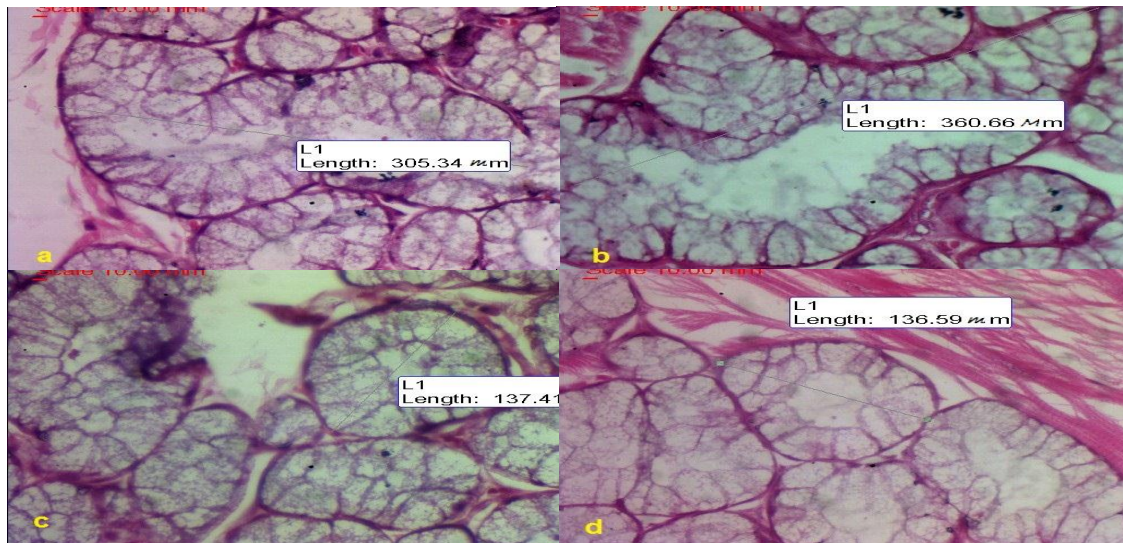


**Figure 2:** Photomicrographs showing the vacuolations and foamy appearance of the cells of secretory acini in group a2 of buccal glands. Hematoxylin and eosin (H&E) stain. X 400.



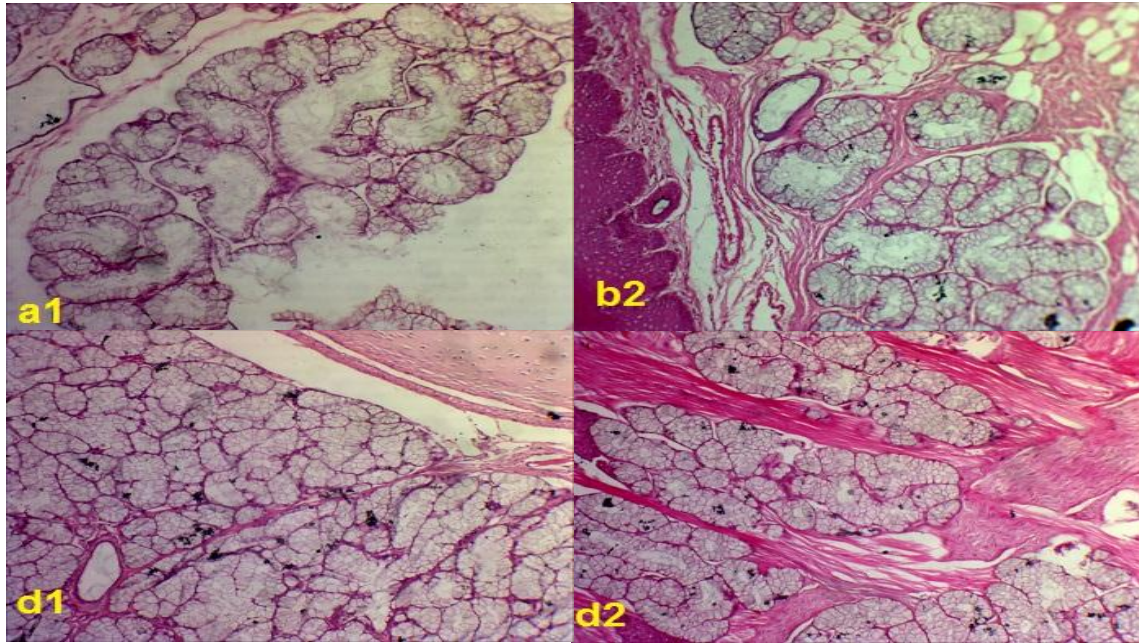


**Figure 3:** Photomicrographs of sections taken from group a2 (soft palatine glands) showing increasing size of acini with wide lumens <arrows>. Hematoxylin and eosin (H&E) stain. X 400.

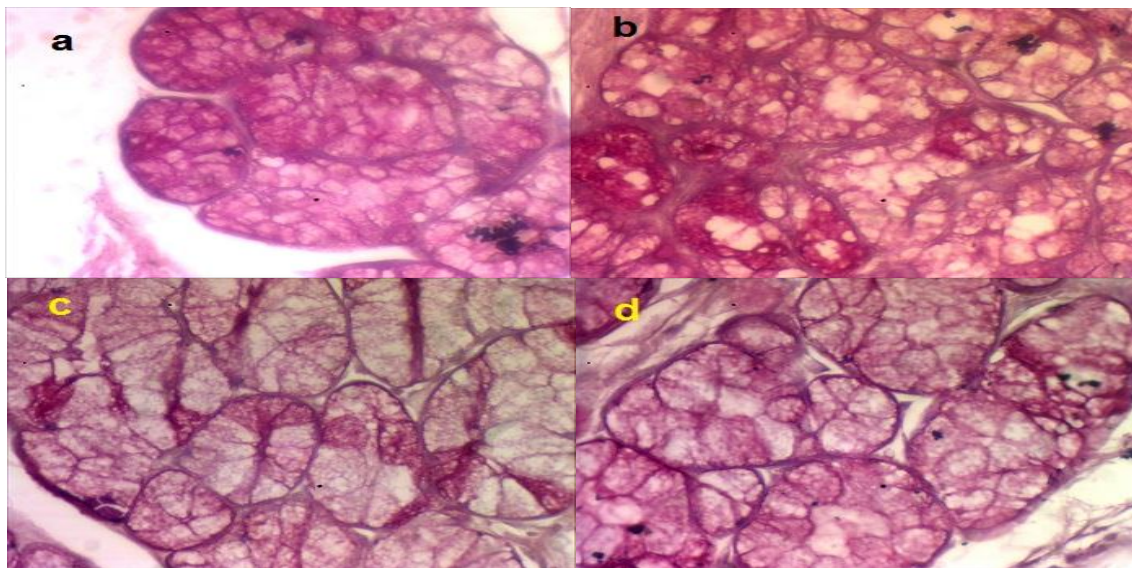


**Figure 4:** Photomicrographs H&E stain. X400 of weber's glands showing the variation of diameters between treated groups Ga2,Gb2 in pictures ( a,b ) and preservative Gc2 in picture (c) , control groups Gd2 in picture (d).

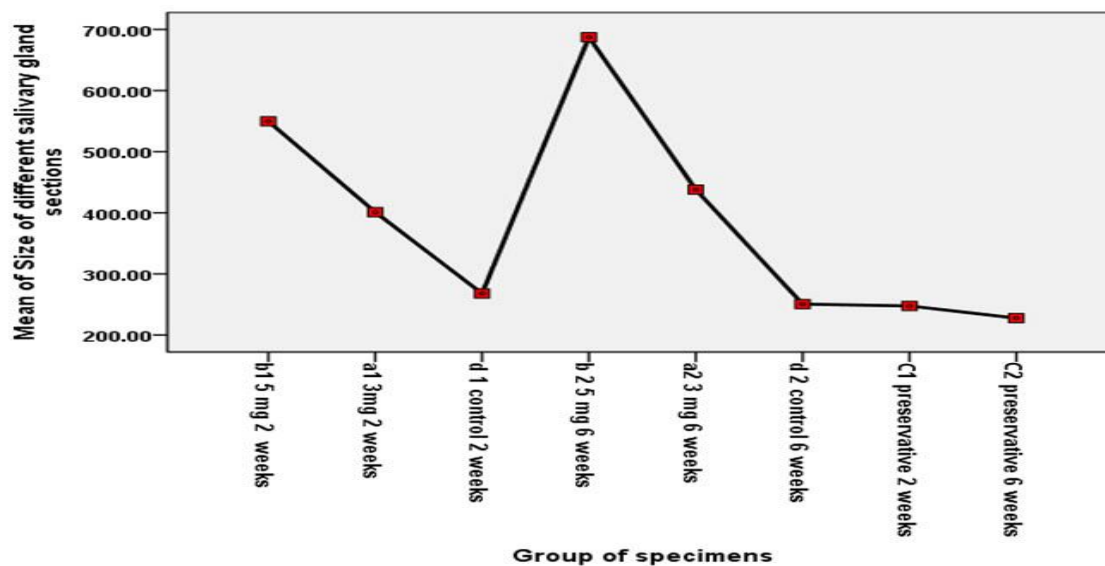




**Figure 5:** Photomicrographs of weber's glands showing spacing ,transformations and increase in diameters of acini in groups(a1, b2) compared with acini in groups(d1, d2). H&E stain. X 100.



**Figure 6:** Photomicrographs showing positive reactions of PAS stain were identified in all groups of the minor salivary glands, and more obvious in treated groups in pictures (a, b) than preservative in picture (c), control in picture (d) groups . X 400.



**Figure 7:** Relationship between the dose of pilocarpine and the mean of the acini diameters of the minor salivary glands

\*\*\*\*\*

**Table 1:** The mean of acini diameters for the three different glands in treated groups were examined in the present study.

The treated groups	Mean of Buccal glands diameters	Mean of Palatal glands diameters	Mean of Weber glands diameters
a1	343 $\mu$ m	430 $\mu$ m	456 $\mu$ m
a2	384 $\mu$ m	473 $\mu$ m	457 $\mu$ m
b1	532 $\mu$ m	532 $\mu$ m	584 $\mu$ m
b2	671 $\mu$ m	677 $\mu$ m	712 $\mu$ m

**Table 2:** The results of ANOVA test applied on the acini diameters of minor salivary glands of the treated and control groups with degree of significance less than 0.001

	Sum of Squares	Mean Square	F	Sig.
Between Groups	3545414.09	506487.73	199.77	.000
Within Groups	344810.39	2535.37		
Total	3890224.48			



**Table 3 :** Descriptive statistics of the measurements of the diameters of groups treated with Pilocarpine & their controls. The readings obtained were in micrometer.

Groups	Number of readings	Mean	Standard deviation	Minimum	Maximum
<b>b1 5 mg 2 weeks</b>	18	549.67	62.37	464.80	699.50
<b>a1 3mg 2 weeks</b>	18	401.09	64.86	307.01	487.00
<b>d 1 control 2 weeks</b>	18	267.95	18.05	232.60	298.41
<b>b 2 5 mg 6 weeks</b>	18	687.30	68.79	577.88	820.70
<b>a2 3 mg 6 weeks</b>	18	437.89	65.70	339.00	556.00
<b>d 2 control 6 weeks</b>	18	250.65	22.34	215.13	289.31
<b>c1 preservative 2 weeks</b>	18	247.56	28.96	201.91	295.80
<b>c2 preservative 6 weeks</b>	18	227.59	38.37	142.06	290.77
<b>Total</b>	144	383.71	164.94	142.06	820.70

**Table 4:** The results of ANOVA a post HOC test, applied on the acini diameters of all groups in 2week.

(I) Group of specimens	(J) Group of specimens	Mean Difference (I-J)	Std. Error	Sig.
<b>d 1 control 2 weeks</b>	b1 5 mg 2 weeks	-281.72611*	16.78415	.000
	a1 3mg 2 weeks	-133.14000*	16.78415	.000
	c1 preservative 2 weeks	20.38833	16.78415	.227

**Table 5:** The results of ANOVA a post HOC test applied on the acini diameters of all groups in 6 week.

(I) Group of specimens	(J) Group of specimens	Mean Difference (I-J)	Std. Error	Sig.
<b>d 2 control 6 weeks</b>	b 2 5 mg 6 weeks	-436.65667*	16.78415	.000
	a2 3 mg 6 weeks	-187.25056*	16.78415	.000
	c2 preservative 6 weeks	23.05333	16.78415	.172

In addition, the use of the Pilocarpine as a pretreatment was protective against irradiation, that illustrated in a previous study performed on the submandibular gland of rat, displaying much less damage after irradiation, with complete recovery after 4 weeks<sup>(16)</sup>.

In 2006, Li et al. revealed that Pilocarpine induced salivary secretions in human by activating  $K^+$  channels, increasing  $Ca^{2+}$  via phospholipase C dependent pathway, and increasing AQP-5 protein expression in the apical membrane of Submandibular gland acinar cells<sup>(17)</sup>. Pilocarpine when injected peripherally, it act directly on salivary glands to induce salivation. However, Inenaga et al. has illustrated that peripherally applied Pilocarpine on the rats does not act only on the salivary glands as a sialogogue, but it can stimulate the thirst sensation by acting centrally to control body fluid balance<sup>(18)</sup>. As well, systemically injected Pilocarpine entered the brain and acted on central muscarinic receptors, has activated autonomic efferent fibers to induce a central stimulation for salivation<sup>(19)</sup>.

Morphometric measurements of the present work have shown a significant enlargement of the acini at treated groups, similar conclusion has been reached by Donath et al., particularly, with sympathetic and parasympathetic stimulation<sup>(20)</sup>. while absence of nerve impulses causes variable atrophic and other metabolic effects on the parenchymal cells<sup>(21)</sup>.

The vasodilatation is a part of secretion, in response to parasympathetic impulses, that usually provides the main stimulus for fluid formation by parenchymal cells, whereas sympathetic nerves have a tendency to increase the output of pre-formed components from certain cells. Related conclusion has been reached by Mills and Quinton<sup>(22)</sup> who pointed that the swelling seen in serous cell of the tracheal serous gland of the rat was related to the accumulation of fluid during intense parasympathetic stimulation. Another study performed on rat parotid gland, emphasized that stimulation with muscarinic and adrenergic agonists causing movement of water and vacuole formation<sup>(23)</sup>. Thus, the end results of water movement might be the main explanation to the increase in size noticed in the Pilocarpine treated rabbits of this study. In view of the fact that vacuole formation is an essential part of water secretion, the vacuolation occurred to a variable degree in certain cells as a normal part of reflex secretion, and frequently found experimentally after strong stimulation<sup>(21)</sup>.

In the present work, there was a pronounced increase in diameter of salivary acini with obvious vacuolation in the cytoplasm of treated groups, which were accompanied by an increase in acinar area, that more obvious on Weber's glands. Soft palatine glands were less affected, while buccal glands were the least to be affected by the drug.

In this study, the positive results of PAS stained sections have shown that there was accumulation of mucopolysaccharides substance, especially in acini of treated groups, that agrees with the study aimed to investigate histomorphological and histochemical structures of three major salivary glands in the adult local rabbits<sup>(24)</sup>. The author has pointed out that the parotid gland acini were reacted positively with PAS stain. Similarly, submandibular and sublingual glands showed PAS positive reaction characterized by magenta color formation of its mucinous contents.

During the inspection to the sections of present work and the pictorial evidence presented for normal untreated and treated rabbit, glands were shown us the difference between the acini of Pilocarpine treated groups and that of normal untreated rabbits.

The production of endogenous saliva has the greatest benefit to patient both for its convenience and importance of natural saliva to oral function, so the clinical observations and histological structure alterations noticed in this study, substantiate the use of Pilocarpine drug in treatment of xerostomia and cases of pre and post radiation therapy in head and neck.

## CONCLUSION

Saliva plays a significant role in the protection of the intraoral structures against injuries caused by various pathogenic microbes, mechanical or chemical irritants, so the maintenance of natural saliva production is very significant role

Although cholinergic agonists Pilocarpine injected peripherally, it can act directly on salivary glands to induce salivation and acts on central muscarinic receptors, activating autonomic efferent fibers to induce a central stimulation for salivation, also affects the thirst centre in the central nervous system.

Pilocarpine as cholinergic agonist (parasympathomimetic) could be used as prophylactic agents, and we also support the usage of the drug in treatment of symptoms of xerostomia from salivary gland hypofunction, xerostomia caused by post radiotherapy treatment of head and neck cancer, and as one of most important choice for treatment of autoimmune diseases like Sjogren's syndrome.

## RECOMMENDATION

Further researches to be done to see the effect of the drug on the major salivary glands and oral mucosa.

The researcher suggests usage the drug for long term, to see the exact structural modifications and other histological changes.

Works still needed to exhibit if the Pilocarpine drug has far reaching effect, or if there is still any histological changes in minor salivary glands after end of treatment.

The inquiry regarding why the Weber's gland of treated groups was the most affected one by Pilocarpine treatment needs more efforts.

## REFERENCES

1. Dawes C. How much saliva is enough for avoidance of Xerostomia? . Caries Research. 2004; 38: 236–240.
2. Dodds M.W, Johnson D.A, Yeh C.K.. Health benefits of saliva: a review. journal of dentistry. 2005Mar ; 33(3): 223-33.
3. Proctor G.B, Carpenter G.H. Regulation of salivary gland function by autonomic nerves . Autonomic Neuroscience: Basic and Clinical .2007; 133 (1) :3-18.
4. Junqueira L. C. ,Cameiro J. Basic Histology.11<sup>th</sup> edition. America : McGraw-Hill; 2005. salivary gland: p 317-321.
5. Eliasson L, Carlen, A. An update on minor salivary gland secretions. Eur J Oral Sci. 2010 ; 118: 435–442.
6. Zhang GH, Castro R. Role of Oral Mucosal Fluid and Electrolyte Absorption and Secretion in Dry Mouth. The Chinese Journal of Dental Research.2015 sep ;18(3):135-54.
7. Guggenheimer J, MOORE P. A.Xerostomia, Etiology, recognition and treatment . American Dental Association. 2003; 134(1):61-69.
8. Berk L. Systemic pilocarpine for treatment of xerostomia. Informa healthcare. 2008; 4(10):1333-1340.
9. Fox P.C. Salivary Enhancement Therapies. Caries Research. 2004; 38:241–246.
10. Laurance D. R. and Bachanch A.L. Evaluation of drug activities: Pharmacometrics. Academic press.1964.
11. IBM Corp. Released 2013. IBM SPSS Statistics for Windows, Version 22.0. Armonk, NY: IBM Corp.
12. Rhodus NL. Oral pilocarpineHCl stimulates labial (minor) salivary gland flow in patients with Sjögren's syndrome. Oral Disease. 1997 Jun ;3 (2) : 93-8.
13. Niedermeier, Matthaeus W, Meyer C, Staar C, Muller S, Schulze R.P, et al. Radiation-induced hyposalivation and its treatment with oral pilocarpine. Oral-Surg-Oral-Med-Oral-Pathol-Oral-Radiol-Endod.1998 Nov ; 86(5): 541-9
14. Horiot J.C, Lipinski F, Schraub S, Maulard-Durdux C, Bensadoun R.J, Ardiet J.M, et al. Post-radiation severe xerostomia relieved by pilocarpine: a prospective French cooperative study. Radiotherapy& Oncology. 2000 Jun ; 55 (3) :233-239 .
15. Johnson J.T, Ferretti G.A, Nethery W.J, Valdez I.H, Fox P.C, David N.G, et al. Oral Pilocarpine for Post-Irradiation Xerostomia in Patients with Head and Neck Cancer. The New England journal of medicine. 1993 Aug; 5,329 (6) :390-395 .
16. Kim K. H, Kim J. Y, Sung M.W, Kim C. W. The Effect of Pilocarpine and Atropine Administration on Radiation-induced Injury of Rat Submandibular Glands. Acta Otolaryngologica.1991; 111( 3) : 967-973 .
17. Li J, Lee S, Choi SY, Lee SJ, Oh SB, Lee JH, et al. Effects of pilocarpine on the secretory acinar cells in human submandibular glands. Life Sciences. 2006 Nov;79 (26) : 2441-2447.
18. Inenaga K, Wakasugi-Sato N, Ono K, Hirase M and Honda E. Intraperitoneal injection of pilocarpine activates neurons in the circumventricular organs and hypothalamus in rats. Brain Research. 2008; 1200 : 51-57.
19. Takakura A.C.T, Moreira T.S, Laitano S.C, De Luca L.A, Jr, A. Renzi A, et al. Central Muscarinic Receptors Signal Pilocarpine-induced Salivation. Journal of Dental Research. 2003 Jun; 82(12): 993-997 .
20. Donath K, Spillner M. and Seifert G. The influence of the autonomic nervous system on the ultrastructure of the parotid acinar cells. VirchowsArchiv. 1974 Mar ;364(1): 15-33.
21. Garrett J.R. The proper role of nerves in salivary secretion: a review. Journals of Dental Research. 1987 Feb; 66 (2) : 387-97.
22. Mills J.W. and Quinton P.M. Formation of stimulus-induced vacuoles in serous cells of tracheal submucosal glands. The American Journal of physiology. 1981 Jul ; 241 (1) :C18-24.
23. Schramm M and Selinger Z. The function of  $\alpha$  and  $\beta$ -adrenergic receptors and a cholinergic receptor in the secretory cells of rat parotid gland. In Advances in Cytopharmacology. 1974;2:29-32.
24. AL-Saffar F.J. Histomorphological and histochemical study of the major salivary glands of adult local rabbits. International Journal of Advanced Research . 2014 Nov; 2(11): 378-402.