



**Libyan Journal of Public Health Practices  
(LJPHP)**

Journal homepage: <https://journals.uob.edu.ly/LJPHP>  
ISSN: 3008-1467 (Online)



Case study

**Corpus Callosum Hematoma in a 4-Year-Old Child Following Road Traffic Accident. A Case Report**

Hind Gazeti<sup>1</sup>, Zinab Elfituri<sup>2\*</sup> and Sufwan Algrmi<sup>3</sup>

<sup>1</sup>Department of Diagnostic Radiology, Faculty of Medicine, University of Zawia, Zawia, Libya

<sup>2</sup>Department of Medical Physiology, Faculty of Medicine, University of Zawia, Zawia, Libya

<sup>3</sup>Department of Surgery, Faculty of Medicine, University of Zawia, Zawia, Libya

**ARTICLE INFO**

**Article history:**

Received 3/9/2024

Revised 26/10/2029,

Accepted 30/10/2024

Available online xxxx

**Keywords:**

Corpus callosum hematoma

Traumatic subarachnoid hemorrhage

Brain CT

Conservative therapy.

**ABSTRACT**

A 4-year-old male child presented to the emergency department at Nawat Al Mustaqbal Hospital in Zawia City, following a head injury sustained in a road traffic accident (RTA). During the initial brain CT scan, a corpus callosum hematoma was detected in the interhemispheric fissure, initially thought to be a traumatic subarachnoid haemorrhage (tSAH). A follow-up brain CT conducted six hours later showed no additional abnormal findings. Subsequently, the patient was transferred to the surgical department for conservative treatment. Following a three-day improvement in his condition, he was discharged. Optimal management for corpus callosum hematoma includes good supportive care, careful clinical follow-up, and prompt recognition of delayed complications to achieve the best neurological outcome.

\* Corresponding author.

E-mail address: [z.elfituri@zu.edu.ly](mailto:z.elfituri@zu.edu.ly) ORCID ID: 0000-0003-0808-490X

## **1. Introduction**

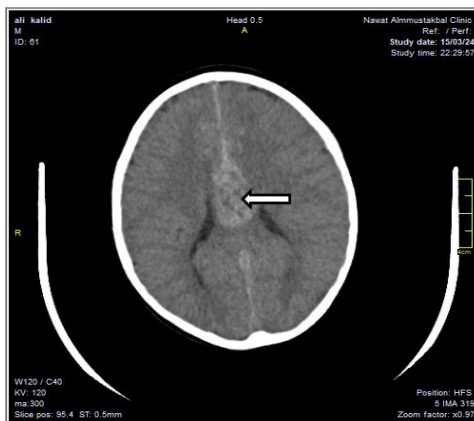
The corpus callosum, a significant structure within the brain, serves as a bridge connecting the two cerebral hemispheres. It comprises approximately 190 million axons, facilitating interhemispheric communication and coordination [1]. Lesions of the corpus callosum are uncommon and can arise from various etiologies. They can be broadly classified into several categories based on their underlying pathophysiology. These include neoplasms, vascular issues, infections, demyelination conditions, leukodystrophy, congenital abnormalities, trauma, and others [2]. Corpus callosum hemorrhage, a rare and serious complication of head trauma, occurs when bleeding accumulates within the corpus callosum. Depending on the location and size of the bleeding, corpus callosum hematoma can cause various neurological sequelae, including seizures, cognitive deficits, and motor impairments [3].

In children, head trauma is a leading cause of morbidity and mortality, and the involvement of the corpus callosum can have severe neurological consequences [4]. Corpus callosum hematoma should be quickly recognized as it is an emergent situation requiring immediate neurosurgical intervention to prevent adverse course and sequelae such as increased intracranial pressure, seizures, and long-term neurologic deficits [5]. Managing corpus callosum hematomas in children is difficult since small children may be unable to articulate their clinical symptoms, which could delay an accurate diagnosis. Hence, radiological tools such as computed tomography (CT), magnetic resonance imaging (MRI), and diffusion tensor imaging (DTI) play a considerable role in the detection of corpus callosum hematoma in the pediatric population with head trauma [6]. CT is frequently employed as the first imaging modality to examine head trauma in children because it is easily accessible, quick, and effective in identifying acute cerebral bleeding [7]. Hyperdense lesions inside the corpus callosum are typical CT findings of the corpus

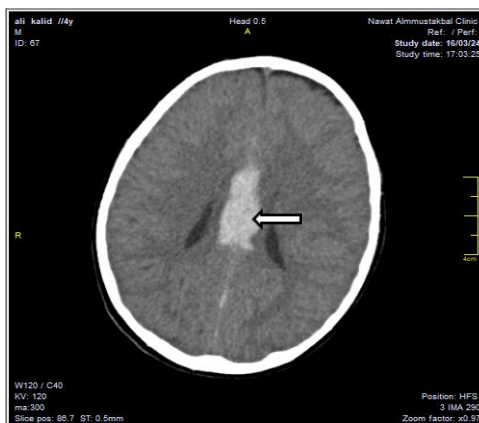
callosum hematoma, with or without extension into the surrounding white matter [8]. Because of its important position and the risk of fast neurological degeneration, corpus callosum hematoma must be treated as soon as possible. Depending on the severity of the bleeding and clinical presentation, medications such as diuretics to reduce edema and osmotic agents to lower intracranial pressure may be administered, as well as, anticonvulsants may be used if seizures develop [9]. However, in extreme situations with life-threatening bleeding or a considerable mass effect (compression of adjacent brain tissue), surgical evacuation of the hematoma may be required [10]. The prognosis for children with corpus callosum hematoma varies greatly according to the severity of the first presentation, the degree of bleeding, and the efficacy of therapy [5]. This case report describes the presentation, investigation, management, and challenges encountered in a child who developed a corpus callosum hematoma following head trauma.

## **2. Case Presentation**

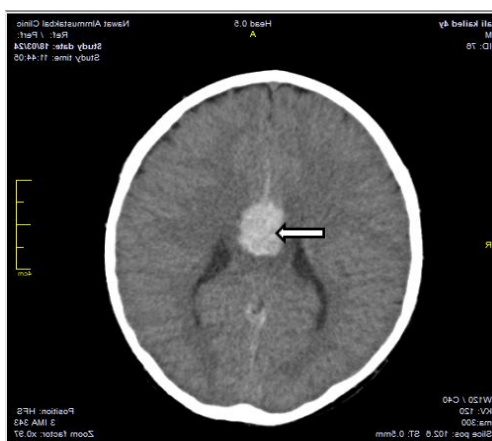
A 4-year-old male Libyan child presented to the emergency department at Nawat Al Mustaqbal Hospital in Zawia City, following a head injury sustained in a road traffic accident. The child was a passenger in a car involved in a collision. On arrival at the emergency department, upon evaluation, he was semiconscious with a Glasgow Coma Scale score of 12. He had no orientation, but his direct and indirect light reflexes were positive and his pupils were of equal size. He responded to painful stimuli and could localize the pain. Initial brain CT did not reveal any epidural, subdural, or parenchymal hematoma or midline shift. However, there was a presence of hematoma in the interhemispheric fissure, which was suspected to be a traumatic subarachnoid hemorrhage (Figure 1). He was admitted to the intensive care unit for supportive treatment, and a follow-up brain CT was performed 6 hours later, revealing no new radio pathological findings (figure 2). After 12 hours he became conscious, and oriented, and complained of intermittent headaches.



**Figure 1.** Initial brain CT showed no epidural or subdural hemorrhage, but a traumatic subarachnoid hemorrhage in the interhemispheric fissure with corpus callosum edema.



**Figure 2.** Brain CT showed a clear interhemispheric hematoma on the corpus callosum, causing neurological disorientation.



**Figure 3.** Brain CT showed a smaller hematoma on the corpus callosum, compared to the previous CT image

The patient was then admitted to the surgical department for conservative therapy before being discharged after three days of improvement in his health, (figure 3) shows the last CT on discharge day.

### 3. Discussion

This case report describes a 4-year-old child who presented with a suspected traumatic subarachnoid hemorrhage (tSAH) after suffering a head injury in a RTA. Although no major intracranial hematomas exist on initial CT scans, blood is identified in the interhemispheric fissure that may indicate a corpus callosum hemorrhage (tSAH).

The child initially presents semiconscious with a Glasgow Coma Scale (GCS) score of 12, indicating a moderate head injury. A responsive light reflex, reaction to pain localization, and improving consciousness within 12 hours were good prognostic signs. The presence of blood in the interhemispheric fissure (corpus callosum hematoma) on the initial CT scan, with no other significant findings, was a typical presentation of a tSAH. A follow-up CT scan with no new abnormalities further increases the suspicion of a tSAH. Routine intensive care unit (ICU) support was a reasonable first approach. Pain management and close observation as an outpatient was an adequate conservative treatment in this case.

The diagnosis of tSAH can be difficult, especially in children. Although CT scans were sensitive in identifying blood within the subarachnoid space, the diagnosis may sometimes need to be confirmed by lumbar puncture and cerebrospinal fluid (CSF) analysis. Lumbar puncture, however, is not routinely performed in all cases as there can be some risk involved with the procedure, particularly in suspected increased intracranial pressure cases.

Despite this child's clinical improvement, long-term follow-up is imperative. Children who have sustained a tSAH may be at higher risk for delayed complications, such as the development of hydrocephalus (fluid accumulation in the brain) or vasospasm (blood vessel narrowing).

Imaging and clinical follow-up to detect these delayed complications is, therefore indicated.

### Conclusion

This case illustrates the importance of maintaining a high index of suspicion for subarachnoid hemorrhage at corpus callosum in the setting of head trauma, even when initial CT findings are normal. Delayed presentations of traumatic subarachnoid hemorrhage have been reported in the literature, and clinical history and examination may lead to important clues. Optimal management includes good supportive care, careful clinical follow-up, and prompt recognition of delayed complications for the best neurologic outcome.

### Conflict of Interest and Financial Disclosure

There are no financial, personal, or professional conflicts of interest to declare.

### References

- 1- Aboitiz, F. (2017). *A Brain for Speech*. Springer. <http://books.google.ie/books>
- 2- Ayaz H, Baker WB, Blaney G, et al. Optical imaging and spectroscopy for the study of the human brain: status report. *Neurophotonics*. 2022;9(S2). doi:10.1117/1.nph.9.s2.s24001
- 3- Cassar-Pullicino V, Oswestry, Uk, Taylor S, Schmidt S. ECR 2014, Part A. *Insights Into Imaging*. 2014;5(S1):1-133. doi:10.1007/s13244-014-0316-6
- 4- Curvelo E, Viana L, De Jesus Santos L, et al. *Communication Disorders Following Traumatic Brain Injury*. In: InTech eBooks. ; 2014. doi:10.5772/57321
- 5- Hamad MK, Takruri DH, Patro SN, Habib MB, Verma V. Corpus callosum hematoma, as a rare complication of COVID-19. *Clinical Case Reports*. 2021;9(12). doi:10.1002/ccr3.5178
- 6- Mandine N, Tavernier E, Hülhagen T, et al. Corpus callosum in children with neurodevelopmental delay: MRI standard qualitative assessment versus automatic quantitative analysis. *European Radiology Experimental*. 2023;7(1). doi:10.1186/s41747-023-00375-4
- 7- Galgano M, Toshkezi G, Qiu X, Russell T, Chin L, Zhao LR. *Traumatic Brain Injury*. *Cell Transplantation*. 2017;26(7):1118-1130. doi:10.1177/0963689717714102

- 8- Pascual JM. Progressive Brain Disorders in Childhood. Cambridge University Press; 2017. <http://books.google.ie/books?id>
- 9- Kadyrova A, Baudinov I, Alin G, Mamytova E , Antipina I , Kyrbasheva I , Toktogaziev B , Bazarbaeva A ,Tagaev T , Vityala Y. Roles of diagnostic imaging techniques in traumatic brain injury. Biomedicine. 2022;42(1):1-10. doi:10.51248/v42i1.1117
- 10- Florian IA, Timis TL, Aldea CC, Florian IS. Preventing Rupture: Clipping of Unruptured Intracranial Aneurysms. In: IntechOpen eBooks. ; 2020. doi:10.5772/intechopen.88038