Libyan Journal of Science & Technology 10:1 (2019) 30–34

Faculty of Science - University of Benghazi

Libyan Journal of Science & Technology

journal home page: www.sc.uob.edu.ly/pages/page/77

Gestational diabetes effect on the histological structure of human Placenta

Halima A. Ali, Ali I. Sati*, Hoda S. Mansur, Saleh S. Muftah, Iman E. Amghaiab

Department of Histology, Faculty of Medicine, University of Benghazi, Libya

Highlights

- **The gestational diabetes environment will affect the syncytiotrophoblast (the cells in contact with maternal blood) and fetal blood (vascular epithelium)**
- **The chorionic villi of the diabetic group were increased considerably by comparison with the normal control group; these changes may be due to aggravation and alternation of physiological hypoxia to pathological hypoxia.**
- **The diabetic placentae revealed considerable vascular congestion and dilation with the main feeding fetal blood vessels, as diabetes is a chronic stress condition that disturbs the effect of vasoconstrictor and vasodilator agents.**
- **The increased rates of perinatal morbidity and mortality were not mainly as placental influence, but considerably because of metabolic abnormalities and complications developed in mother and fetus due to diabetes.**

ARTICLE INFO

Article history:

Received 05 October 2019
Revised 01 December 2019
Accepted 15 December 2019
Available online 28 December 2019

Keywords:

Human placentae, Gestational diabetes, Chorionic villi, Histological changes.

Address of correspondence:

E-mail address: Ali.i.sati@u.o.b.edu.ly

A. I. Sati

ABSTRACT

Many studies have been carried on the placenta of diabetic mothers to determine the changes in placenta structure as an adaptation to the diabetic environment. These changes are one of the detrimental fetal outcomes regardless of the good care of diabetic women. The aim of this study is to recognize the histological changes in the placenta of pregnant women with gestational diabetes and the effect of these changes on fetal and neonatal mortality and morbidity. The study was done on 30 placentae from diagnosed pregnant women with gestational diabetes treated with insulin. The control group involves 30 placentae obtained from normal healthy women. Both groups of placentae were full-term and post caesarean delivery. The biopsies of the placentae were collected from the central and peripheral regions and treated to obtain paraffin sections, and then stained with Masson's Trichrome stain. Under a light microscope, the sections were examined and photographed by using a digital camera. An increase in chorionic villi vasculature and a number of young villi were observed in the placentae of diabetic group. These changes could clarify the increase of morbidity and mortality in fetal and neonate associated with diabetes. On the other hand, these histological changes could be modifying changes as it has been shown that functions of the placenta were not severely distressed, as a result, of diabetes, as there are compensative adjusting responses.

1. Introduction

The placenta is regarded as one of the complex organs and as a result, it is difficult to understand and it is a vital metabolic function in pregnancy. It manufactures various types of hormones, controls the transport of maternal nutrients to the fetus and assists maternal metabolic adaptations to different stages of pregnancy (Murphy *et al.*, 2006). The diabetic woman's placenta had attracted much interest mainly because it is considered that placental damage may be associated with the high incidence of fetal complications that occur during pregnancies complicated by diabetes mellitus (Jones *et al.*, 1976). The metabolic pathway of the glucose and oxygen show disruption in pregnancies with type I diabetes mellitus, as a consequence of this the placental villous growth and function are affected (Vambergue *et al.*, 2011; Myatt *et al.*, 2000; Leach *et al.*, 2004). Diabetes is considered as a condition of chronic oxidative stress, therefore the vasculature of fetal placenta of diabetic mother response to vasoconstrictor and vasodilator agents are extensively attenuated compared to the normal placenta (Metzger *et al.*, 1998; Kossenjans *et al.*, 2000). Classical morphological examinations of the structure of diabetic placenta have revealed a variable degree of changes in the syncytiotrophoblast, cytotrophoblast, trophoblastic basement membrane, and fetal blood vessels (Jacomo *et al.*, 1976; Jones *et al.*, 1976; Honda *et al.*, 1992; Laurini *et al.*, 1987). Some researchers establish no significant difference in microscopic villous changes (Makhseed *et al.*, 2002); especially in women with good glycemic control (Verma *et al.*, 2011). Generally, the majority of researches accounted a relative placental immaturity, due most likely to a high proportion of villi with stromal edema (Jacomo *et al.*, 1976; Jones *et al.*, 1976; Laurini *et al.*, 1987; Stoz *et al.*, 1987; Younes *et al.*, 1996) and focal fibrinoid necrosis (Jones *et al.*, 1976; Stoz *et al.*, 1987; Al-Okail *et al*, 1994; Younes *et al.*, 1996). At the same time as there are many studies that reveal the placental adaptive responses to gestational diabetes, but the exact way by which these adaptive responses at the placental level stay vague (Myatt, 2006)

2. Aims and Objectives

The purpose of this research is to explore the various histological and some histochemical changes in the placentae of pregnant women accompanied by diabetes and to analyze and assess some mechanisms of the placental adaptation in response to the effect of gestational diabetes.

3. Material and Methods

This study was carried out on 60 placentae from full-term post-cesarean section deliveries that were divided into two groups:
Gestational diabetic group: there is a group of 30 placentae from women diagnosed with gestational diabetes mellitus and all women were treated with zinc insulin. All were chosen randomly of different age with no other complications of pregnancies as taken from their history and investigations.

© 2019 University of Benghazi. All rights reserved. ISSN 2663-1407; National Library of Libya, Legal number: 390/2018

The control group: composed of 30 placentae were obtained from normal healthy women. All women were additionally assessed by history taking, vital signs records, and investigation. The placentae were presented to the Histology Department at Benghazi University after a post-delivery examination for a further histological study where biopsies were obtained from peripheral and central.

4. Histological Methods

Formalin saline with 10% concentration was used to fix the peripheral and central placental biopsies for 1-2 days then dehydrated in alcohols (50-100%) with escalate grades. Clearance was obtained with xylene then impregnation and embedding were performed to obtain solid blocks by three successive changes of soft paraffin at 50˚C. Rotatory microtome was used to prepare five micrometer-thick serial sections that mounted on albumin glycerol-covered glass slides prepared for staining using Masson's Trichrome stain. The obtained sections were examined using a light microscope and photographed by a digital camera.

5. Results

By comparing between normal placenta (Fig. 1 and 2) and gestational diabetic placenta (Fig. 3 and 4) by using Masson's Trichrome stain, the gestational diabetic placenta showed a moderate decrease in the fibrinoid material in the capsule at central sections while the peripheral capsule was slightly thickened and acquired thick fibrinoid material coating it externally (Fig. 3A and 4A). The peripheral capsule showed mild stromal edema spaces (Fig. 4A). The appearance of the subcapsular and main blood vessels were dilated and congested with blood (Fig. 3A, C and 4C). The chorionic villi were increased in number and branching at the central diabetic placenta more than the peripheral diabetic placenta with more frequent syncytial clumps. The villous capillaries were more increased peripherally than centrally while the villous stroma was more increased (mainly collagen) centrally than peripherally (Fig. 3B and 4B). The villous capillaries at central placental areas were more congested with fetal blood (increased polycythemia) more than the peripheral villous capillaries (Fig. 3B and 4B). The villous stroma was more increased at central villi more than that at peripheral villi with mild edema spaces centrally and moderate stromal edema spaces peripherally (Fig. 3C and 4C). The central intervillous spaces and sinuses appeared more congested with maternal blood (increased polycythemia) than the peripheral spaces (Fig. 3B, 3C and 4B).

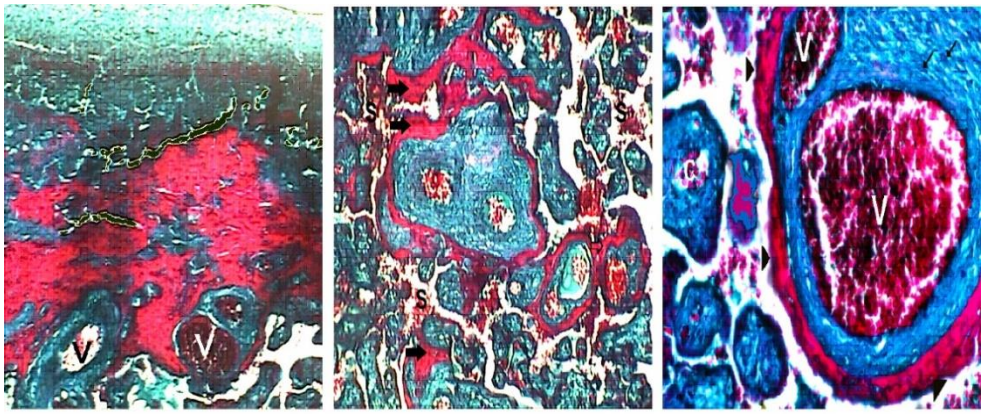

Fig. 1. The central sections of a full-term normal placenta photomicrograph illustrated

A: The capsule was normal in thickness with its collagen content (blue) and the composition of fibrinoid (pinkish red).with subcapsular blood vessels (V) appeared normal size. **B**: The chorionic villi and villous blood capillaries were normal with scant volume of maternal blood in the intervillous capillary sinuses (S). The collagen fibers (blue) were found in villous stroma although the fibrinoid (arrows) material had the appearance of encircling around big anchoring villi. **C**: The chorionic villi and villous capillaries (C) were normal. The villous stroma accommodates normal content of collagen (blue) and fibroblasts (arrows) while the fibrinoid (arrowheads) material appeared circumferential envelop the trabeculae containing the main feeding blood vessels (V) that appeared normal with full of blood mostly RBCs (x100, x150, x500, Masson's Trichrome).

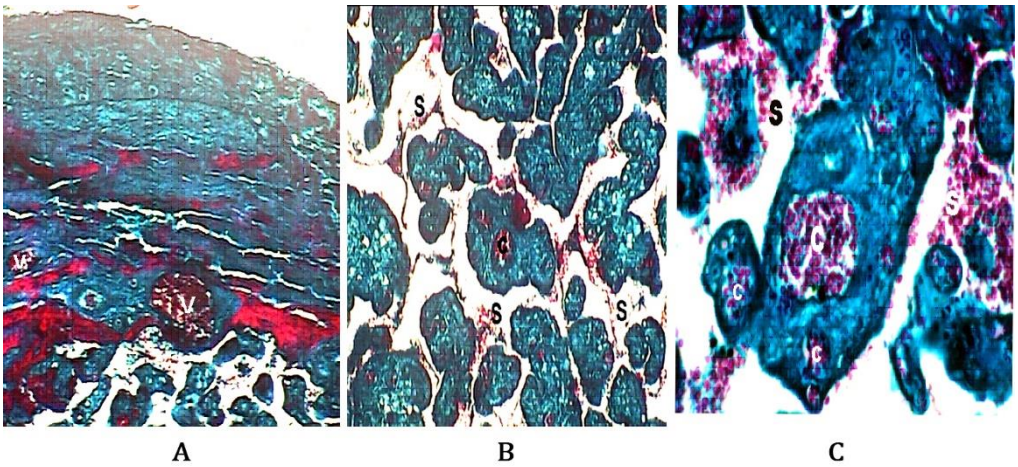

Fig. 2. Photomicrograph of peripheral sections of normal full-term placenta showed

A: The capsule was normal in thickness with its collagen content (blue). The fibrinoid (pinkish red) composition seen mainly in the deep area of the capsule. The subscapular blood vessels (V). **B**: The chorionic villi were normal together with villous capillaries (C) and stroma was formed mainly from collagen (blue). No marked fibrinoid material around the villi. The sinuses of intervillous capillaries were enclosed with less amount of maternal blood (S). **C**: The chorionic villi were normal together with villous capillaries (C) and stroma was formed mainly from collagen fibers (blue). The sinuses of intervillous capillaries were enclosed with less volume of maternal blood (x100, x200, x500, Masson's Trichrome).

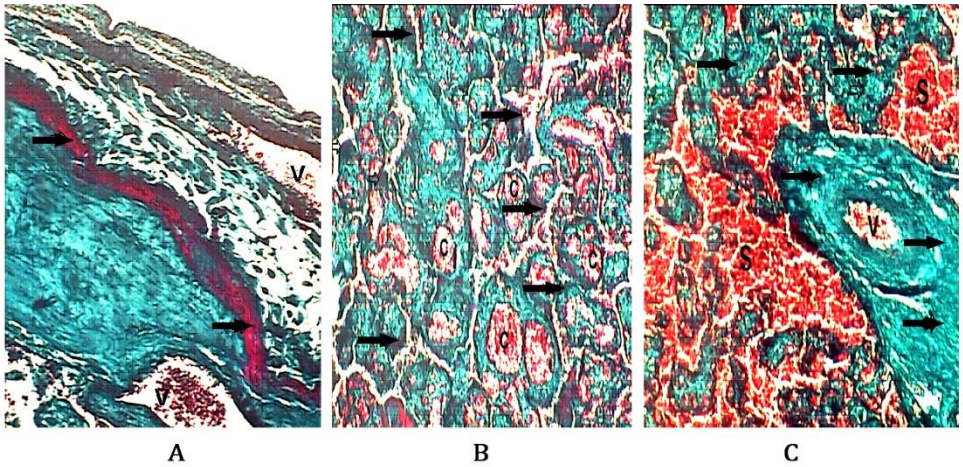

Fig. 3. The central sections of placenta in diabetic full-term placenta photomicrograph exhibited

A: Capsule was normal in thickness with its collagen (blue) although the content of fibrinoid (arrows)(pinkish red) was slightly declined. The appearance of the subcapsular blood vessels (V) was dilated and congested with blood. **B**: The crowded villi with increased stromal content mostly collagen (blue). The villous capillaries (C) were congested and dilated. Syncytial clumps were frequent and appeared as dark knots (arrows). **C**: The intervillous spaces and sinuses (S) were congested and engorged with maternal blood especially at the subchorial (basal) areas where the main feeding vessel (V) was present. The villi and trabeculae showed high collagen content (arrows) (x100, x100, x100, Masson's Trichrome).

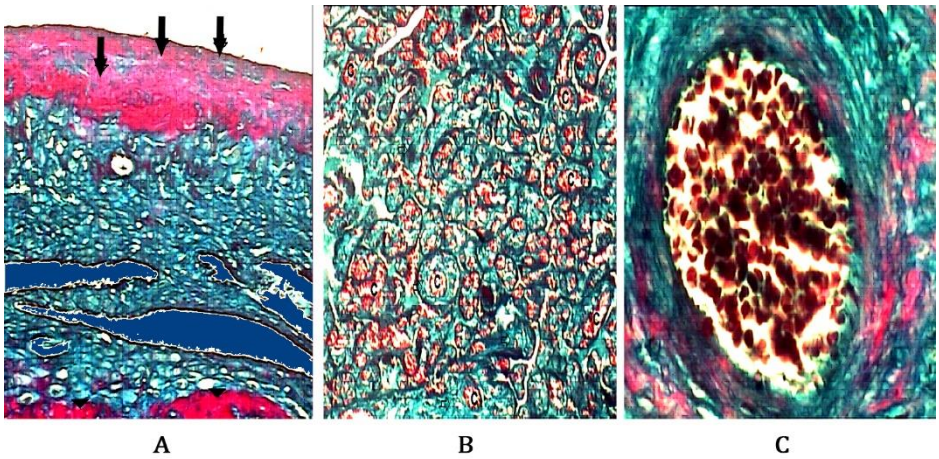

Fig. 4. Photomicrograph of peripheral sections of diabetic full-term placenta showed

A: capsule was meagerly thickened with its collagen (blue). The fibrinoid (pinkish red) composition was more raised at the peripheral circumferential area (arrows) and at the deep part was normal (arrowheads). **B**: The number of young villi was raised with abundant villous capillaries (C) with less capsule (stroma) (arrows). **C**: Main feeding blood vessel appeared congested and dilated with a fair amount of collagen (greenish blue) and fibrinoid (pinkish red) material. The fetal polycythemic blood contained mostly of mature RBCs (brownish red) (x100, x100, x500, Masson's Trichrome).

6. Discussion

The placenta is considered as the most important record of prenatal history for baby and mother (Wilczynski *et al*., 1998). It is distributing nutrient supplements and waste metabolite products between mother and fetal circulation. Furthermore, the placenta provides many peptide and steroid hormones that enhance fetal, placental and maternal metabolism (Myatt, 2006). The gestational diabetes environment will affect the syncytiotrophoblast (The cells in contact with maternal blood) and fetal blood (vascular epithelium) because of the receptors, ion channels and many other molecules that present on both placental surfaces (Desoye *et al*., 2005). The chorionic villi of the diabetic group were increased considerably by comparison with the normal control group. Horizontally, these villi were further cramped with a higher content of stroma in the centre than peripheral although the peripheral microvasculature was increased more than villous vasculature in the centre. Despite, the higher raise was in association with the terminal and intermediate villi, they were immature and unspecific with approximately lower syncytiovascular membranes of parenchyma. On the other hand, the increased number of villi described a rise in the volume of villous, villous syncytial surface area and total volume of trophoblast. These findings were compatible with the abundance of other researches (Casson *et al*., 1997; Lind, 1989; Teasdale, 1981; Teasdale, 1983; Desoye *et al*., 2005). Villous changes in association with the placenta of the diabetic patients may be assigned to aggravation and alternation of physiological hypoxia (that is normally needed for vasculogenesis, organogenesis, angiogenesis and trophoblast development) to pathological hypoxia, which initiates more oxidative and nitrative stresses. Therefore, pathological hypoxia could exaggerate expression of the placental growth factor (PLGF), angiogenic vascular endothelial growth factor (VEGF) and angiopoietins, causing raise in the volume and extension of villi and hypercapillarization of their vasculature (branching angiogenesis). Fetoplacental angiogenesis could be transformed through bone marrow angioblasts activation i.e. endothelial precursor cells (EPCs) or via capillary sprouts from the pre-existing vessels by the current endothelial cell or the enclosing pericytes. This could demonstrate one adjusting response of the diabetic placenta to raise its performance as regard production of hormone, substrate metabolism and activity of transporter in uteroplacental circulation as well as fetoplacental blood circulation. Other researchers were similarly clarified the later adaptive response (Myatt, 2006; Charnock-Jones *et al*., 2004; Benirschke *et al*., 1995; Adelman *et al*., 2000).

Moreover, Peripheral areas of the diabetic placenta obtained higher villous vasculature (angiogenesis and hypercapillarization)

in comparison with central regions, which could be due to increased hypoxia presented at the peripheral regions that would be more aggravated by diabetes. Furthermore, the increased vasculature occurred particulary as longitudinal vascular growth without remodeling, as had been established by some earlier studies (Myatt, 2006; Benirschke *et al*.,1995; Adelman *et al*., 2000).

The diabetic placentae exhibited considerable vascular congestion (plethora) and dilation with the main feeding fetal blood vessels (central, basal and subcapsular areas), also villous capillaries, especially at subcapsular and basal areas. Similarly, the intervillous spaces (IVS) and sinuses were raised in volume and congested with maternal blood, which could be a result of secondary polycythemia of mother, uteroplacental endarteritis and the adjuvant relatively diminished drainage of uteroplacental blood. These results were in line with some previous researches (Jones *et al*., 1976; Stoz *et al*., 1987; Teasdale, 1981; Cormack, 2001).

Plethora (Congestion) of fetoplacental blood vessels could be associated with aggravation of secondary polcythemia that should happen normally at a physiological level. Diabetes might lead to distress hypoxia, nitrative stress, oxidative stress and impaired transport of glucose, amino acids and oxygen as well as secondary absolute polycythemia, congestion or plethora, hyperglycemic edema and hypocalcemia, which together shared in dilatation of fetoplacental blood vessels by insulting their vascular smooth muscle. This was in harmony with (Metzger *et al*., 1998) who illustrated that diabetes is a chronic stress condition that disturbs the effect of vasoconstrictor and vasodilator agents on vasculature of fetal placenta when related to the normal placenta.

The cells of villous capillaries (endothelial cells) had flattened appearance with intact normal-thickness basal lamina along with the control group, as had been illustrated by other researchers (Desoya *et al*., 2005; Benirschke *et al*., 1995; Adelman, 2000). On the other hand, the endothelial cells of capillaries at the diabetic placenta appeared more flattened as a result of vasodilation and congestion. Furthermore, the basement membrane of these cells appeared intact and thickened as an effect of diabetic microangiopathy. These data were in consonance with numerous earlier studies (Myatt *et al*., 2000; Leach *et al*., 2004; Jacomo *et al*., 1976; Jones *et al*., 1976; Teasdale, 1981; Adelman *et al*., 2000; Madamba, 1987; Mayhew *et al*., 2000; Cormack, 2001) who stated thickening of basement membrane in endothelial cell, defective in permeability of capillary and endothelial dysfunction by cause of all types of diabetes mellitus.

7. Conclusion

The placenta plays an important role in fetal development, which could have a significant effect on the development of morbidity and mortality in adult life. From the current study and its association with the prior research we can assume that the placental functions were not critically affected as redeeming adaptive responses of gestational diabetes had compensated properly. Therefore, the increased rates of perinatal morbidity and mortality were not mainly as a placental influence, but considerably because of metabolic abnormalities and complications developed in mother and fetus due to diabetes. In diabetic care, diagnosis at an early stage and controlled internal placental measures were the critical guides that have to be considered in the limitation of the diabetes impairment effect.

References

Adelman, D. M., Gertsenstein, M., Nagy, A., Simon, M. C, Maltepe, E., (2000) 'Placental cell fates are regulated in vivo by HIF-mediated hypoxia responses', *Genes Dev*., 14, pp. 3191-3203.

Al-Okail, M. S., AL-Attas, O. S., (1994) 'Histological changes in placenta syncytiotrophoblasts of poorly controlled gestational diabetic patients', *Endocr J*., 41, pp. 355-360.

Benirschke, K., Kauffmann, P., (1995) Maternal diseases complicating pregnancy: diabetes, tumors, preeclampsia, lups anticoagulant, in: K. Bernischke, P. Kaufmann (Eds.), Pathology of the human placenta, 3rd ed., Springer-Verlag, New York, pp. 476–536.

Casson, I. F., Clarke, C. A., Howard, C.V., McKendrick, O., Pennycook, S., Pharoah, P. O., Platt, M. J., Stanisstreet, M., van Velszen, D., Walkinshaw, S. (1997) 'Outcomes of pregnancy in insulin-dependent diabetic women: result of a five-population cohort study', *BMJ*, 315, pp. 274-280.

Charnock-Jones, D. S., Kaufmann, P., Mayhew, T. M., (2004) 'Aspects of human fetoplacental vasculogenesis and angiogenesis. 1. Molecular regulation', *Placenta*, 25, pp. 103-113.

Cormack DH.,(2001). Essential Histology. 2nd ed. Toronto. Canada; J. B. Lippincott and Wilkins Company, Philadelphia.

Desoye, G., Kaufmann, P. (2005) The Human Placenta in Diabetes. Djelmis J, Desoye G, Ivanisevic M (Eds): Diabetology of Pregnancy. Front Diabetes Basel, Karger, vol 17; pp. 94-109.

Honda, M., Yoyoda, C., Nakabayshi, M., Omori, Y. (1992) 'Quantitative investigations of placenta terminal villi in maternal diabetes mellitus by scanning and transmission electron microscopy', *Tohoku J Exp Med*., 167, pp. 247-57.

Jacomo, K. H., Benedeetti, W. L., Sala, M. A., Alvaez, H. (1976) 'Pathology of the trophoblast and fetal vessels of the placenta in maternal diabetes mellitus', *Acta Diabetol Lat.*, 13, pp. 216-235.

Jones, C. J. B., Fox, H. (1976) 'Placental changes in gestational diabetes; An ultrastructural study', *Obstet Gynecol*., 48, pp. 274-280.

Jones, P., Fox, H. (1976) 'An ultrastructural and ultrahistochemical study of the placenta of the diabetic woman', *Journal of Pathology*, 119, pp. 91-99.

Kossenjans, W., Eis A., Sahay, R., Brockman, D., and Myatt L. (2000) 'Role of peroxynitrite in altered fetal-placental vascular reactivity in diabetes or preeclampsia', *American Journal of Physiology-Heart and Circulatory Physiology*, 278, pp. 1311-1319

Laurini, R. N., Visser, G. H., van Ballegooie, E., Schoots, C. J. (1987) 'Morphological finding in placenta of insulin-dependent diabetic patients treated with continuous subcutaneous insulin infusion (CSII)', *Placenta*, 8, pp. 153-65.

Leach, L., Gray, C., Staton, S., Babawale, M. O., Gruchy, A., Foster C., Mayhew, T. M., James, D. K. (2004) 'Vascular endothelial cadherin and beta-catenin in human fetoplacental vessels of pregnancies complicated by type 1 diabetes: association with angiogenesis and perturbed barrier function', *Diabetologia*, 47, 4, pp. 695-709.

Lind T. (1989) A prospective multicenter study to determine the influence of pregnancy upon the 75-gram oral glucose tolerance test. In: Sutherland HW, Stowers J M, Pearson DWM. (Eds). Carbohydrate metabolism in pregnancy and newborn IV. Berlin: Springer, pp. 209-226

Madamba, A. M. R., (1987) Histometria del sustrato morfologico del intercombio resperatorio en placenta de la diabetes gestacional. University de Navarra (Spain). Thesis.7: 205 pages.

Makhseed, M., Musini, V. M., Ahmed, M. A., AL-Harmi, J. (2002) 'Placental pathology in relation to the White's classification of diabetes mellitus', *Arch Gynecol Obstet*, 266, pp. 136-140.

Mayhew, T. M., Jariram, I. C. (2000) 'Stereological comparison of 3D spatial relationships involving villi and intervillous pores in human placenta from control and diabetic pregnancies', *J Anat*, 197, pp. 263-274.

Metzger, B. E., Coustan, D. R. (1998) 'Proceedings of the fourth international workshop-conference on gestational diabetes mellitus', *Diabetes*, 21 (Suppl. 2), B1–167.

Murphy, V. E., Smith, R., Giles, W. B., Clifton, V. L. (2006) 'Endocrine Regulation of Human Fetal Growth: The Role of the Mother, Placenta, and Fetus', *Endocrine Reviews*, 27, pp. 141–169.

Myatt L., (2006). Placental adaptive responses and fetal programming. J Physiol. 572(Pt 1):25-30.

Myatt, L., Kossenjans, W., Sahay, R., Eis, A., Brockman, D. (2000) 'Oxidative stress causes vascular dysfunction in the placenta', *J Matern Fetal Med*., 9, pp. 79-82.

Stoz, F., Schuhmann, R. A., Schmid, A. (1987) 'Morphometric investigation of terminal villi of diabetic placenta in relation to the White classification of diabetes mellitus', *J Perinat Med*,15, pp. 193-198.

Teasdale, F. (1983) 'Histomorphometry of the human placenta in class B diabetes mellitus', *Placenta*, 4, pp. 1–12.

Teasdale, F. (1981) 'Histomorphometry of the placenta of the diabetic woman: class A diabetes mellitus', Placenta 2, pp. 241–252.

Vambergue, A. and Fajardy I. (2011) 'Consequences of gestational and pregestational diabetes on placental function and birth weight', *World J Diabetes*, 2(11), pp. 196-203.

Verma, R., Mishra, S., Kaul, J. M. (2011) 'Ultrastructural Changes in the Placental Membrane in Pregnancies Associated with Diabetes', *Int. J. Morphol.,* 29(4),1398-1407.

Wilczynski, J., Podciechowski, L., Krekora, M., Wenerski, J., Czichos, E., Kulig, A., Zielinski, K. (1998) 'Macroscopic estimation of placenta using morphometric grid. Part I: pre-pregnancy and post-pregnancy diabetes mellitus', *Ginekol Pol*, 69(12), pp 974-981.

Younes, B., Baez-Giangreco, A., Al-Nuaim, L., Al-Hakeem, A., Abu Talib, Z., (1996) 'Basement membrane thickening in the placentae from diabetic women', *Pathol Int*., 46(2), pp. 100-104.