Libyan Journal of Science & Technology 9:2 (2019) 149–154

Faculty of Science - University of Benghazi

Libyan Journal of Science & Technology

journal home page: www.sc.uob.edu.ly/pages/page/77

Anatomical Studies of the Gastrointestinal Tract of snake *Malpolon monspessulanus insignitus* (Geoffroy, 1809)

Ezaldin A. M. Mohammed [a,*], Youssef K. A. Abd-Alhafid [a], Hamed A. N. Jala [b]

[a]*Zoology Department, Faculty of Science, Omar Al-Mukhtar University, Al Bayda, Libya.*

[b]*Zoology Department, Faculty of Science, Azzaytuna University, Tarhona, Libya*

Highlights

- **The gastrointestinal tract is a straight tubular organ from oral cavity to cloaca.**
- **The wall of the esophagus, stomach, small intestine and large intestine was built up of the following layers from outside inwards; serosa, muscularis, submucosa and mucosa**
- **The entire length of the gastrointestinal tract was lined by simple columnar epithelium (ciliated in the esophagus) and contains goblet cells except in the stomach and rectum where these cells are absent.**
- **In the small intestine, lining the mucosa consists of three types of cells. Simple vertical cells, cup cells and lymph nodes.**

ARTICLE INFO

Article history:

Received 04 October 2018
Revised 15 June 2019
Accepted 27 June 2019
Available online 29 June 2019

Keywords:

Anatomical, Gastrointestinal Tract, *Malpolon monspessulanus insignitus*.

* Corresponding author:

E-mail address: ezaldine5@gmail.com
E. A. Mohammed

ABSTRACT

Studies aim to study the morphometrical and anatomical features of a gastrointestinal tract *of Malpolon insignitus*, and compared with that of other examined reptiles So, It is clear that the tissues in the gastrointestinal tract adapt to feed the meat. The wall of the esophagus, stomach, small intestine, and large intestine is a buildup of four layers from outside inwards are serosa, muscularies, submucosa and mucosa. The esophagus was longer than the stomach and It may measure one-quarter the body length of the snake it is highly stretch to facilitate movement the food to the stomach. The mucosal epithelium was consist of simple and compound stomach glands and consist of three types of glands; they are the cardiac glands, pyloric glands, and fundus glands. The majority of the mucosal folds were primary folds as for secondary folds were rare. The small intestine is long on and that of the animal is purely carnivorous. The small intestine is composed of short transverse loops in snakes. The intestine consists of many longitudinal folds that allow the surface area to increase digestion. The mucosa of the small intestine members in the form of leaf-like villi provided with shallow branched Lieberkühn crypts at their bases. It consists of three types of cells; the endocrine cells, the goblet and the absorptive. The large intestine is short and has a larger diameter and consists of colon and rectum. The mucous membrane of the colon consists of cavernous and vertical cells, while that of the rectum is, straight and is rich in lymph spaces and goblet cells.

1. Introduction

Snakes have an important role in preserving the environment, as they play a role in the ecological balance and feed them on rodents and insects (Shine., 1995; Farooq *et al*., 2007). The diversity of snakes is not fully explored in Libya. The increased use the reclaimed land area at the expense of the natural environment of wild animals of the increased use pesticides and chemical fertilizers has significantly threatened the lives of these animals (Akram and Qureshi, 1995; Farooq *et al*., 2007). Despite the destruction of their environment, snakes remain abundant in most parts of Africa (Farooq *et al*., 2007; Amr and Disi, 2011). Snake *Malpolon insignitus* it brown color soft texture long and medium movement. Eyes are relatively large and surrounded by armor (Schleich, H. H., 1987). Frontal twice to two and a half as long as broad, about half as broad, in the middle, as the subocular, as long as or a little longer than its remoteness from the end of the snout, as long as the parietals. Loreal three to four times as long as deep (Cottone and Bauer, 2009). The maximum length may reach 200 cm. (Carranza *et al.*, 2006). In Libya, *Malpolon insignitus* is found in mountainous and coastal areas and is very common in forest areas where as well as agricultural areas it can easily get its prey (Schnurrenberger and Hans, 1963), see Fig. 1.

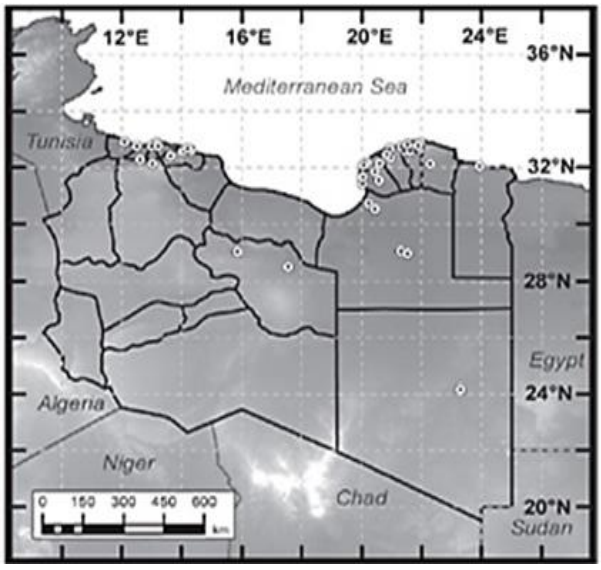

Fig. 1. Distribution of *Malpolon insignitus* in Libya, Schnurrenberger and Hans, (1963)

© 2019 University of Benghazi. All rights reserved. ISSN 2663-1407; National Library of Libya, Legal number: 390/2018

An agile and active daytime predator he strong and courageous, a force of up to 16 kilometers per hour when chasing prey (Sindaco *et al.*, 2013). Prey Species includes Insects, lizards, small birds, rodents and other Small snakes (Nagy *et al.*, 2004). They are a venomous species, but venomous is not dangerous to humans, and the best defense in response to threats is its speed to escape (Bauer *et al.*, 2017).

The digestive system is responsible to break up and absorb the nutrients into the bloodstream in the diet of the snake for use by the metabolism and energy production of the body (Kardong, 2002). The mouth is the beginning of the digestive system and in it begins digestion where the secretion of digestive enzymes working on the decomposition of prey after being fixed my teeth. (Zug *et al.*, 2001). The venom gland produces Poisoning enzymes that are injected into the prey working to paralysis, kill prey, and then begin the process of digestion (Goin, 1962; Spellerberg, 1982; Mehrtens, 1987). The esophagus receives food from a mouth, Waves of contraction of the relatively long esophagus coupled delivers food to stomach (Romer, A. S. and Parsons T., 1986). Then to the large intestine. From there the waste enters the colon, which comes out of the cloaca. (Kardong, 2002).

2. Materials and methods

The animal used in this studying is the *Malpolon monspessulanus insignitus* (Geoffroy, 1809). It was caught localities in Wasita region, 20 km from Bayda City, Libya. Only adult-stage specimens were used [total body length (TL), 164±20 cm and total weight, 1150±100 g]. *Malpolon insignitus* were anesthetized by an overdose of 0.05% tricaine methane sulfonate by injection under the skin. Animals were dissected and the different regions of the alimentary canal; esophagus, stomach, Parts of the gastrointestinal tract of the esophagus, Stomach, the small intestine and the large in Bouin's fluid and were subjected to processing for sectioning. Section 7 µm thick were stained with haematoxylin and eosin.

3. Results

Anatomical observations

- *Malpolon monspessulanus* is a type of snake that changes its skin, a family of Colubridae. It is a poisonous opistoglifa snake. It is rarely involved in human poisoning. Since the quality of the toxins is ineffective for large mammals. The male and female adult samples were about 1.60 m long. Her weight was about 1.40 kg. The tail represents about 1/4 of the total length with a a uniform dark brown or light brown color, males are larger than females (Fig. 2a).
- The head of *Malpolon monspessulanus* is Looks like hanging, and bears eight large dorsal shields, the head shields are of great importance in Knowing the type of snake and taxonomy, It is called shields (Rostral, Internasal, Nasal, Parietal reocular, Prefrontal, Supraocular and Frontal, parietal) (Fig. 2b).
- The digestive system directly inside the snake's mouth is the buccal cavity. This is known as the esophagus of the snake. In snakes, the esophagus is long and can be half-length of the body. The esophagus connects to the anterior region of the stomach, which in turn connects to the intestines, the rectum and finally the cloaca.
- The esophagus has a relatively thin wall and as the axial musculature plays a role in the transportation of food to the stomach, it becomes muscular. The esophagus is extremely distensible to allow large prey. The mean length of the esophagus was 40±5 cm. The only distinguishing feature between the stomach and esophagus is that the stomach has a glandular mucosa. The esophagus is fusiform, having longitudinal folds (proximal esophagus) and broad and flat folds (distal esophagus).
- The stomach is responsible for the secretion of digestion enzymes, and the stomach is clear as it has a diameter larger than the intestines and also have large folds allow to increase their size when entering food, and the length of the stomach about 20 cm. The stomach is divided into four regions: the cardiac region continued with the esophagus, the long saccular body with a terminal region, and the pyloric region continuous with the intestine.
- The intestine was continues the digesting process started in the stomach. It has extensive longitudinal folds to increase surface area for absorption and allows distension to accommodate large prey; the mean length was 55±5 cm. The transition from small intestines to the large intestines was clear. The spleen is adherent to the pancreas, forming the splenopancreas. The pancreas is found caudal to the pylorus, near the gallbladder and spleen those three organs being referred to as the triad. Cloaca is the terminus of the gastrointestinal tract. In snakes, the cloaca is linear rather than round and is divided into three sections by mucosal folds: urodeum, coprodeum and proctodeum (Fig. 2c).

Fig. 2 (a) Snake *Malpolon monspessufanus insignitus* (Geoffroy, 1809).

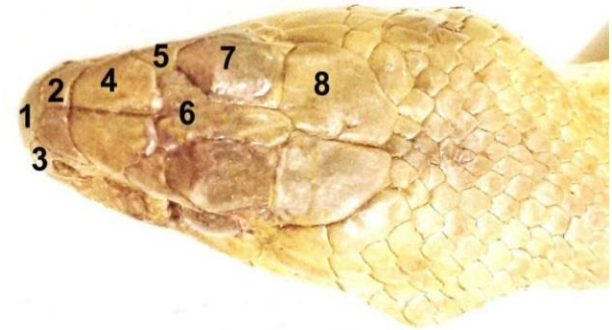

Fig. 2. (b) *Malpolon monspessulanus*. Top of head called shields: 1- Rostral. 2- Internasal. 3- Nasal. 4- Parietal reocular. 5- Prefrontal. 6- Supraocular. 7- Frontal. 8- Parietal.

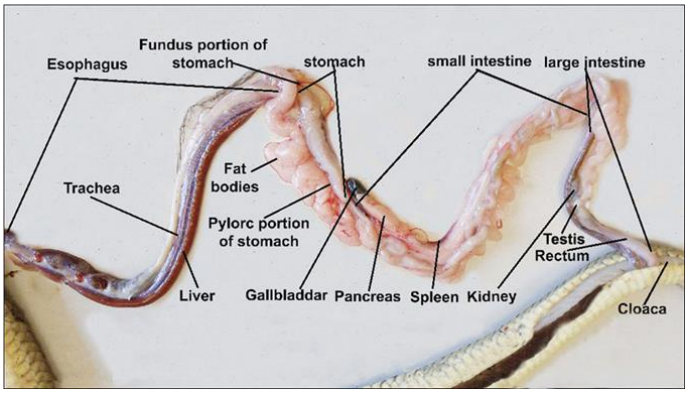

Fig. 2. (c) Gastrointestinal Tract of snake *Malpolon monspessulanus* insugnitus (Geoffroy, 1809)

Histological observations

- Esophagus: The esophagus was composed of four layers; mucosa, submucosa, muscularis, and serosa. The majority of the mucosal folds were primary folds, and secondary folds were

rare. The mucosal epithelium was composed of stratified cells; there were no glands in the wall of the esophagus. Brush cells were present among the columnar epithelial cells in the distal portion of the esophagus. The muscularis was composed of an inner longitudinal layer and an outer circular) layer, both of which were striated muscles (Fig. 3).

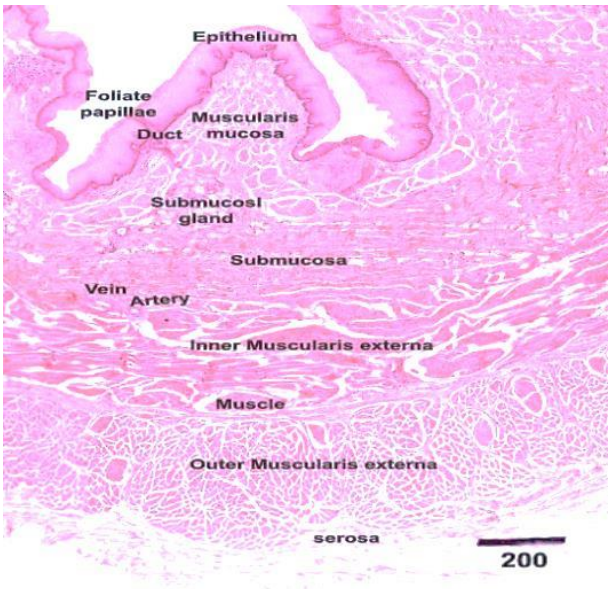

Fig. 3. Photomicrograph in the oesophagus of psammophis schokari. H&E stain.

- Stomach: All regions of the stomach had four layers; mucosa, submucosa, muscularis, and serosa. From the esophagus to the cardiac region of the stomach, cells comprising the mucosal epithelium transitioned from stratified cells mixed with saccular mucous cells to simple columnar cells (Fig. 4a).

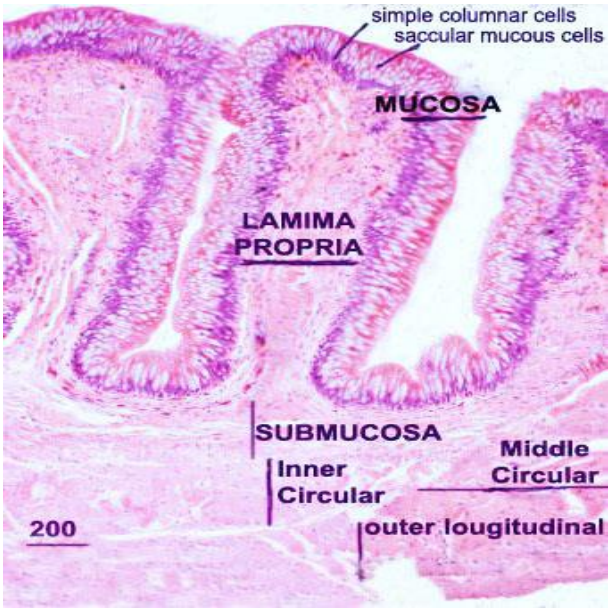

Fig. 4. (a) LM in the esophagus the terminal region of the stomach. H&E stain

- The inner longitudinal striated muscle layer in the esophagus was present within the submucosa in the cardiac region of the stomach. The circular striated muscle layer is finished at the beginning of the stomach in a cardiac region of the stomach.
- The cardiac region of stomach: Is the first part is the cardia which surrounds the cardial orifice, the mucosal epithelium composed of simple columnar epithelial cells, and no goblet cells were observed within the lamina propria which is atypical loose connective tissue. The muscularis was composed of inner longitudinal, middle circular and outer longitudinal layers (Fig. 4b).

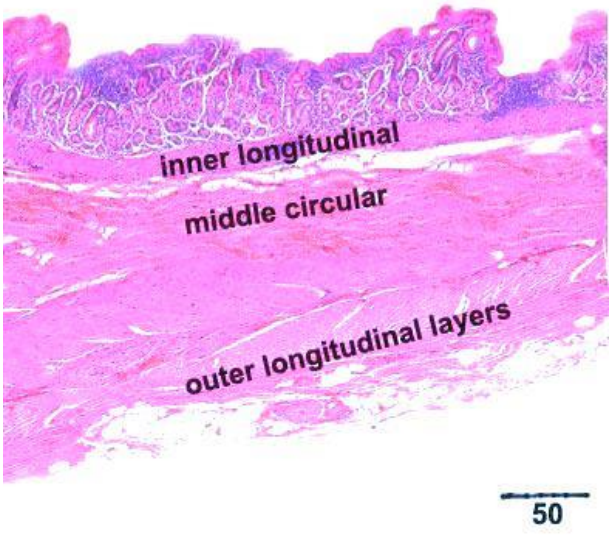

Fig. 4. (b) muscularis in the cardiac region of stomach. E&E stain.

- The Stomach layers consisted of both longitudinal and circular smooth muscle layers, the circular smooth muscle layers were thin when they are compared with smooth muscle layer in the body region of the stomach, the longitudinal smooth muscle was considerably thicker when compared with smooth muscle layer in the body region of the stomach, and a muscularis mucosa was not observed. The pyloric region of the stomach: The mucosal epithelium was composed of simple columnar cells, and no gastric glands were observed within the lamina propria (Figs. 4c & 4d).

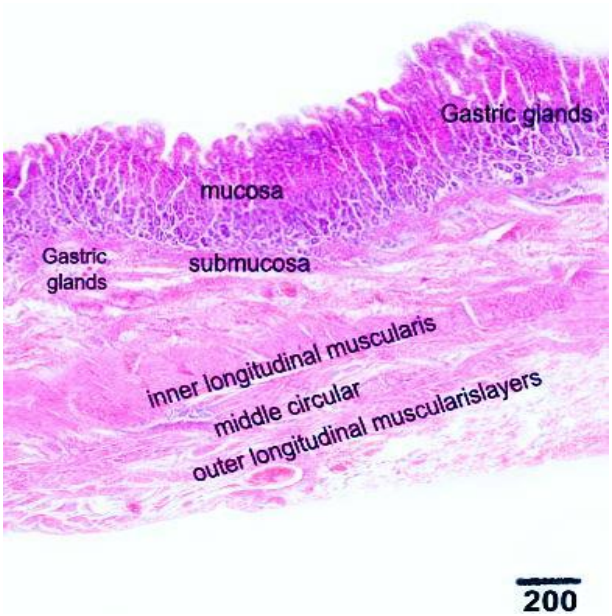

Fig. 4. (c) The body region of the stomach. H&E stain.

- The small intestine is a long and narrow 'tube' with a structure and epithelium that maximises surface area due to the presence of many largely longitudinal folds. Ileocecal valve is absent in *Malpolon insignitus*. The small intestine is composed of four layers typically present in the alimentary system. Its four layers are the mucosa, submucosa, the smooth muscles and serous membrane.
- The muscularis was composed of inner circular and outer longitudinal layers. The circular and longitudinal layer was as thick. The intestinal epithelium presenting a large number of

goblet cells with mucopolysaccharides. The intestine had many branched and intensive villi, which was a very thick wall when compared to the stomach (Figs. 5a & 5b).

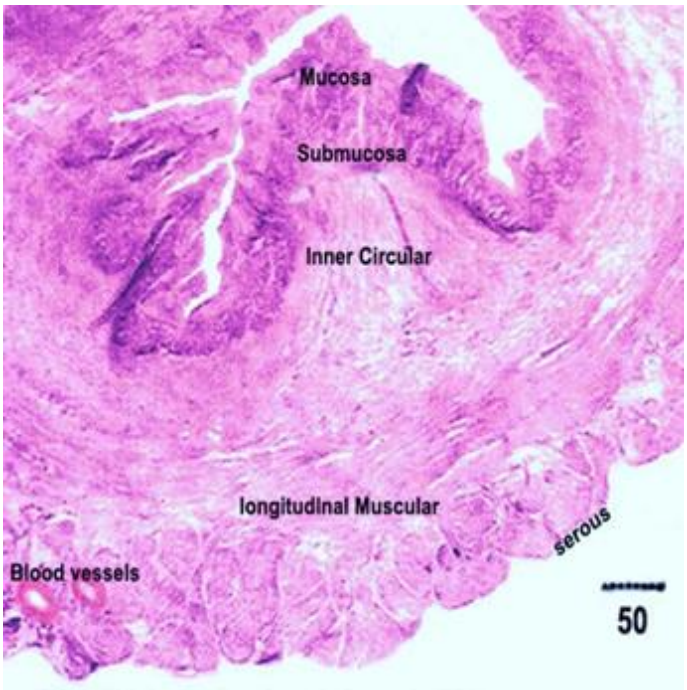

Fig. 4. (d) Terminal region of stomach. H&E

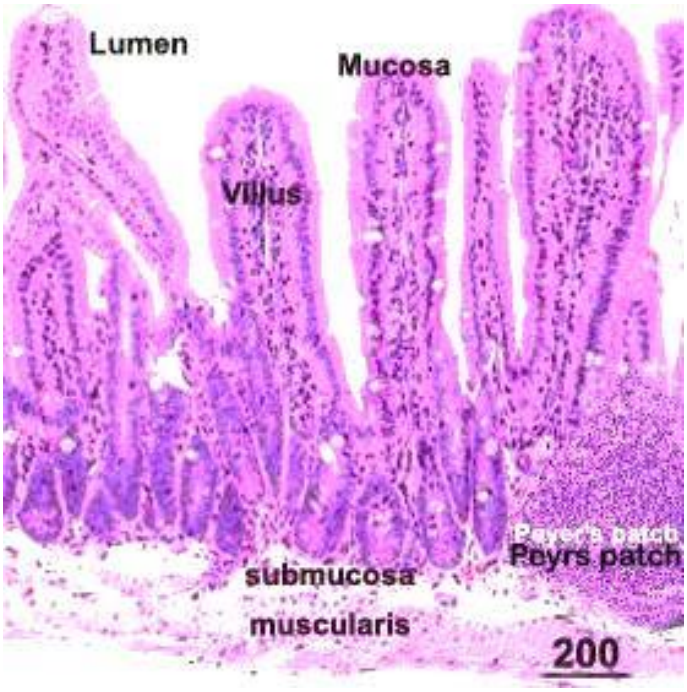

Fig. 5. (a). Anterior intestine. H&E stain

- Large Intestine: The mucous showed villi and an intestinal wall thin when compared to the Small intestine and Short and unclear primary folds were observed. The intestinal epithelium presenting a little of simple columnar cells and numerous goblet cells. The muscularis was composed of inner circular and outer longitudinal layers. Both layers were thinner than those of the anterior intestine. The inner longitudinal striated muscle layer in the cardiac region of the stomach is an extension of the inner longitudinal striated muscle layer in the esophagus (Figs. 5c & 5d).

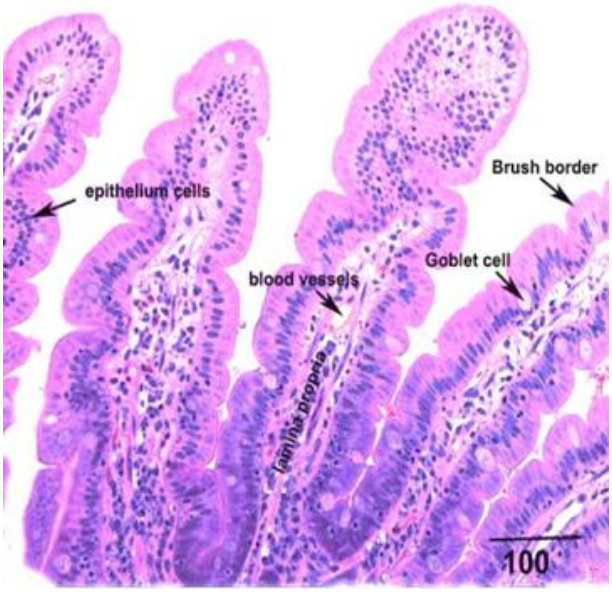

Fig. 5. (b) Simple columnar epithelim cell and few goblet cells

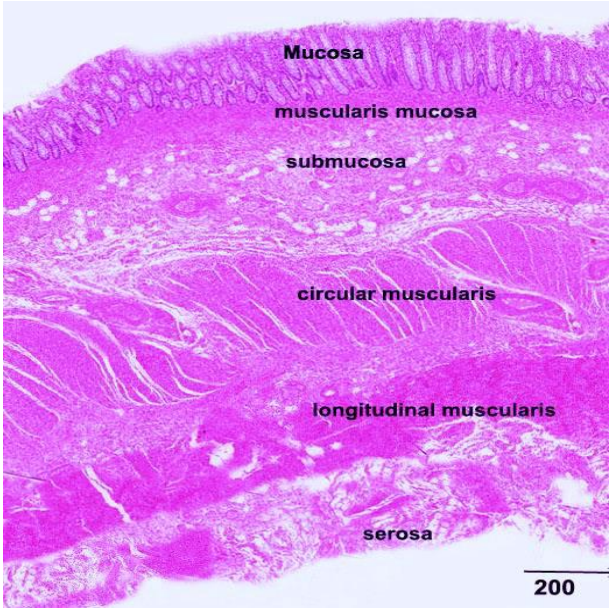

Fig. 5. (c). Posterior intestine. H&E stain.

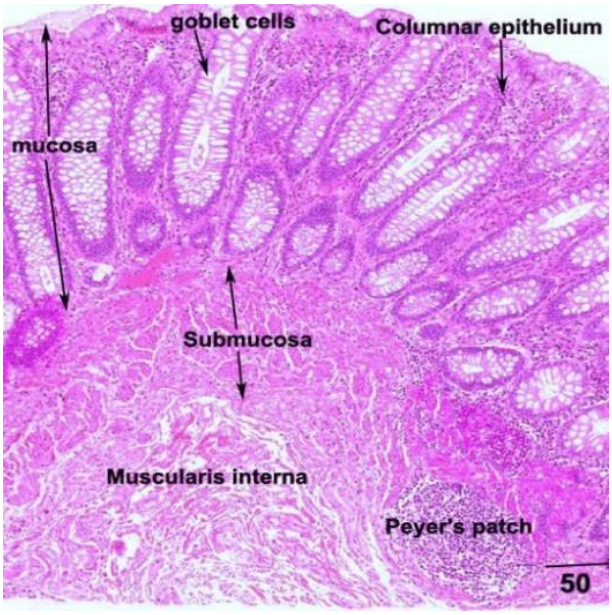

Fig. 5. (d). Posterior intestine. H&E stain.

4. Discussion

Histological examination of the oesophageal mucsa of species of reptiles showed a considerable difference in their histological structure. The present study and examination revealed that the oesophageal mucosa of the colubrid snake *Malpolon insignitus* is represented by goblet cells and simple columnar ciliated (Khamas, 2011; Reeves, 2011). Such a structure is similar to the observations obtained in Mauremys (Taib, N. T. Jarrar, B. and EL- Ghandour, M. H., 1985). Caspica (Taib and Jarrar., 1983), Acanthodactylus and Cnalcides (Dehlawi and Zaher, 1989). However, in Uromastyx aegyptia (EL-Toubi and Bishai, 1958), Chameleon vulgaris (Bishai, 1960) and in Uromastyx philbyi (Farag, 1982). Only the anterior region of the esophageal mucosa assumes structure is similar to the observations obtained, while the posterior region was found to consist of a layer of goblet cells and ciliated columnar. This latter layer is followed by two or three layers of replacing cells (Al-Nassar, 1976). Thus, comparing the data obtained by this experiment with the available literature, it is possible to conclude that the findings described here confirm that the predominant esophagus-lining epithelium of the studied samples was prismatic simple epithelium, which is compatible with previous works (Frye., 1991; Abdeen, *et al*., 2013), although no pseudostratified epithelium has been found, as described by Khamas and Reeves (2011). In *Malpolon monspessulanus insignitus*, the oesophageal mucosa is only primarily of mucous secreting cells (goblet cells). Moreover, in the snake Natrix natrix, and Vipera berus (Dehlawi and Zaher, 1989), the ciliated cylindrical cellsoccurring in the anterior portion of the oesophagus are replaced posteriorly by large mucous cells and simple squamous cells on the surface and more cubical cells devoid of cilia. In many snakes' species, the posterior portion of the oesophagus is devoid of ciliated cells (Dehlawi and Zaher, 1989; Dilmuhamedov, 1975).

The presence of oesophageal glands in reptiles, in general, was a matter of great dispute between several authors. The present Observational Study revealed the absence of such glands as in many previous examined reptiles as in Alligators (Beguin, F. 1904), Ablephorius pannonicus (Greschik, E., 1917), Scincus officinalis (El-Toubi, M. R., 1936), Typhlops vermicularis, Agama stellio (Heyder, G., 1974), the colubrid snak N. natrix and V. berus (Dehlawi and Zaher, 1989).

The esophageal wall exhibited a thickening in the cranial-caudal sense, especially regarding the muscle layer and, secondarily, the muscularis mucosae and even the adventitia, according to the terms used by Jacobson (2007), as similarly found in this work Abdeen *et al*., (2013) describes that the esophageal-gastric transition is abrupt and that the mucosa of the gastric fundus, the main glandular portion of the organ, is composed of stratified columnar epithelium with cylindrical cells and glands, which, in turn, are outlined by neck cells (Frye, 1991; Jacobson, 2007). These gastric glands exhibit two clearly distinguishable cell types: one characterized by dark cells (pale blue stain or light basophilia) and the other by light cells (eosinophilic) (Frye, 1991; Jacobson, 2007). The points of the discrepancy between the cited works involve the types and functions of the cells present in the gastric glands, the characterization of the cardiac and pyloric portions and finally the number of layers of the muscularis mucosae.

The esophagus and cardia could not be distinguished, as pylorus and fundus could not either. Frye (1991) and Helmstetter *et al*., (2009) describe the cardia as an epithelium identical to the esophagus, with an abrupt transition to the glandular epithelium of the fundic portion, which, in turn, is the major glandular portion of the stomach. The pyloric portion is characterized by a discrete reduction in the number of gastric glands, epithelial projections resembling intestinal folds, and a lining with a single, strongly eosinophilic cell type (Frye, 1991). Thus with respect to the fundus and the pylorus, the descriptions are very similar, in the sense of the present study. However, Jacobson (2007) divided the stomach only in fundus and pylorus, with the latter portion characterized by shorter and less branched glands, still poorly distinguishable from the anterior portion.

This apparent discrepancy seems merely nominal to us and not analytical, given that Jacobson (2007) simply did not name the transition between the esophagus and cardia, as it is histologically indistinguishable and only macroscopically visible. The abrupt microscopic transition, which is a consensus between both works cited, occurs only between the cardia and the fundus, corroborating the findings of the present study. Concerning the cell types constituting the gastric glands, the samples examined in the present study exhibited one type composed of a pale and heterogeneous cytoplasm.

In lower part of the epithelial tissue of the small intestine, muscularis mucosa was narrow and composed of a layer of smooth muscle cells. Similar to other reptiles, muscularis layer of small intestine was smooth and consisted of two layers (Putterill and Soley, 2003). There were no glands in the small intestine of H. cyanocincyus as indicated by Holmberg *et al*., 2002. The mucosal epithelium of large intestine was Existence up simple columnar cells with several sporadic goblet (Firmiano *et al*., 2011).

Abdeen *et al*., (2013) while studying the large intestine of the Ramphotyphlops braminus snake reported that in mucosa, a thin layer of muscle was present, which is the same layer as muscularis mucosa in this study. Then, was the submucosa layer, which is equivalent to the connective tissue, rich in blood vessels. Muscularis was made of a thick layer of longitudinal cells on the inside and a thin layer of circular cells on the outside. Serosa was located in the outermost part of the wall. Similar to most reptiles, the intestinal gland in the large intestine was not found in H. cyanocinctus (Gasperetti, 1988; Hamdi *et al*., 2014).

References

Abdeen, A. M., Mostafa, N. A., Abo-Eleneen, R. E., Elsadany, D. A. (2013) 'Anatomical studies on the alimentary tract of the Egyptian Typhlopid Snake', *Journal of American Science*, 9, 5, pp. 504-517, doi: 10.7537/marsjas090513.65.

Akram, S. and Qureshi, J. (1995) Snake-Nittagun, 27, pp. 25-30.

Al-Nassar, N. A. (1976) Anatomical studies osteology and gut histology of the amphisbaenian Diplometopon zarudnyi inhibiting Kuwait. M.Sc. Thesis, Kuwait University.

Amr, Z. and Disi, A. M. (2011) 'Systematics, distribution and ecology of the snakes of Jordan', *Vertebrate Zoology*, 61, pp. 179-266

Bauer, Aaron M., Jonathan C. Deboer, Dylan J. Taylor (2017) 'Atlas of the Reptiles of Libya. Proc', *Cal. Acad. Sci*., 64(8), pp. 255-256.

Beguin, F. (1904) 'L intestine pendant le jeune et l intestine pendant la digestion. Etudes faites sur le Crapaud de joucs et le lezard des murailles', *Arch. Anat. Micr*., 6, pp. 385-454.

Bishai, H. (1960) 'The anatomy and histology of the alimentary tract of Chameleon vulgaris', *Fac., Sci., Cairo Univ*., 15(29), pp. 44-61.

Carranza, S., Arnold, E. N. and Pleguezuelos, J. M. (2006) 'Phylogeny, biogeography, and evolution of two Mediterranean snakes, *Malpolon monspessulanus* and Hemorrhois hippocrepis (Squamata, Colubridae), using mtDNA sequences', *Molecular Phylogenetics and Evolution*., 40(2), pp. 532–546. doi:10.1016/j.ympev.2006.03.028. PMID 16679033.

Cottone, A. M. and Bauer, A. M. (2009) 'Sexual size dimorphism, diet, and reproductive biology of the Afro-Asian Sand Snake, Psammophis schokari (Psammophiidae)', Amphibia-Reptilia, *Leiden*, 30, pp. 331-340.

Dehlawi, G. Y. and Zaher, M. M. (1989) 'Histological studies on the alimentary tract of the colubrid snake, Coluber florudentus (Family: Colubridae)', *Proceedings of the Zoological Society. A. R. Egypt*, (1), pp. 95-112

Dilmuhamedov, M. E. (1975) The comparative morphology of the digestive tract of some reptiles. Dissertation, Alma-Ata.

El-Toubi, M. and Bishai, H. (1958) The anatomy and histology of the alimentary tract of the lizard Uromastyx aegyptia Forskal, *Bull. Fac. Sci*. 34, pp. 5-13.

EL-Toubi, M. R. (1936) Macroscopic and microscopic anatomy of Scincus officinalis. M.Sc. Thesis, Fac. Sci, Cairo University.

Farag, A. A. (1982) Histological studies on the mucosal epithelium of the anmentary tract of the agamid lizard, Uromastyx philbyi parker. The Annals of Zoology. Published by Academy of Zoology. XLX, (1), pp. 1-23.

Farooq, Z., Akram, S. M. and Tahir, T. (2007) Ecological Assortment of Snakes in Southern Punjab, Pakistan. Life Sci. Int. J., 1, pp. 330-334.

Firmiano, E. M., Cardoso, N. N., Vieira, D. A., Sales, A., Santos, M. A. (2011) 'Histological study of the liver of the lizard, Tropidurus torquatus Wied 1820, (Squamata: Tropiduridae)', *Journal of Morphological Science*, 28, pp. 165-170.

Frye, F. L. (1991) Reptile care: an atlas of diseases and treatments. Neptune: TFH Publications,

Goin, C. (1962). Introduction to Herpetology. San Francisco: W.H. Freeman and Company

Greschik, E. (1917) Uber den Darmkanal von Albepharus pannonicus Fritz, und Anguis fragilis L. *Anat. Anz*., 50, pp. 70-80.

Hamdi, H., El-Ghareeb, A. W., Zaher, M., Essa, A., Lahsik, S. (2014) 'Anatomical, histological and histochemical adaptations of the reptilian alimentary canal to their food habits: II-Chamaeleona fricanus', *World Applied Sciences Journal*, 30, pp. 1306-1316.

Helmstetter, C., Reix, N., Tflachebba, M. Pope, R. K.; Secor, S. M.; Le maho, Y.; Lignot, J. H. (2009) 'Functional changes with feeding in the gastro-intestinal epithelia of the Burmese python (Python molurus)', *Zoological Science*, 26, 9, pp. 632-638. doi: 10.1242/jeb.015313.

Heyder G. (1974) 'Das verdaungs system Von Typhlops vermiucularis Marrem. 1920', *Morph Journal of biology*, 120, pp. 185-197.

Holmberg, A., Kaim, J., Persson, A., Jensen, J. (2002) 'Effects of digestive status on the reptilian gut. Comparative Biochemistry and Physiology Part A', *Molecular & Integrative Physiology*, 133, pp. 499-518.

Jacobson, E. R. (2007) Infectious diseases and pathology of reptiles: color atlas and text. Boca Raton: CRC Press. https://doi.org/10.1201/9781420004038

Kardong, Kenneth V. Ph.D. (2002) Vertebrates-Comparative Anatomy, Function, Evolution. 3rd Ed. McGraw Hill: New York.

Khamas, W., Reeves R. (2011) 'Morphological study of the esophagus and stomach of the gopher snake pituophis catenifer', *Journal of Veterinary Medicine Series C: Anatomia Histologia Embryologia*, 40, 4, pp. 307-313. doi: 10.1111/j.

Mehrtns, J. M. (1987) Living Snakes of the World in Color. New York City, NY, USA: Sterling Publishers: 480.

Nagy, Z. T., Lawson, R., Joger, U. & Wink, M. (2004) 'Molecular systematics of racers, whipsnakes and relatives (Rep tilia: Colubridae) using mitochondrial and nuclear markers', *Journal of Zoological Systematics and Evolutionary Research*, 42, pp. 223 – 233.

Putterill, J. F., Soley, J. T. (2003) 'General morphology of the oral cavity of the Nile crocodile, Crocodylus niloticus (Laurenti, 1768). I. Palate and gingivae Onderstepoort', *Journal of veterinary research*, 70, pp. 281-297.

Romer, A. S. and Parsons, T. (1986) The Vertebrate Body. W.S. Saunders Co. Philadelphia. 679.

Schnurrenberger, Hans. (1963) 'Fishes, amphibians, and reptiles of two Libyan oases', *Herpetologica*, 18(4), pp. 270-273.

Shine, R. (1995) Australian snakes: A natural history. Cornell University Press.

Sindaco, R. & Venchi, A. & Grieco, C. (2013) The reptiles of the Western Palearctic. 2. Annotated checklist and distributional atlas of the snakes of Europe, North Africa, Middle East and Central Asia, with an update of the vol. 1.

Spellerberg, I. (1982) Biology of Reptiles. NY: Chapman and Hall, spring 2010.

Taib, N. T. and Jarrar, B. (1983) 'Morphology and histology of the alimentary canal of Mauremys caspica (Reptilia, Emydidae)', *Ind. J. Zool*., 11, pp. 1-12.

Taib, N. T. Jarrar, B., and EL-Ghandour, M. H. (1985) 'Morphology and histology of the alimentary canal of Chalcides levitoni (Reptilia, Emydidae)', *Bangladesh J. Zool*., 10, pp. 1-14

Zug, George R., Laurie J. Vitt, Janalee P. Caldwell (2001) Herpetology–An Introductory Biology of Amphibians and Reptiles.2nd Ed. Academic Press: California.