Libyan Journal of Science & Technology 11:2 (2020) 126–135

Faculty of Science - University of Benghazi

Libyan Journal of Science & Technology

journal home page: www.sc.uob.edu.ly/pages/page/77

Opinions and attitudes of general dental practitioners in Libya towards the intracanal separation of endodontic instruments

Ibtesam O. Orafi

Department of Conservative and Endodontic, Faculty of Dentistry, University of Benghazi

E-mail: ibtesam.orafi@uob.edu.ly

Highlights

- **The current study investigates the opinions and attitudes of general dental practitioners regarding the separated instruments while performing root canal treatment.**
- **Complications during attempts of retrieval of separated instruments.**
- **Shed the light on the importance of further training courses on the different conservative approaches for instrument retrieval.**
- **Educational courses on the benefits of the use of dental operating microscope while retrieving separated instruments are highly recommended.**

ARTICLE INFO

Article history:

Received 09 July 2020
Revised 20 September 2020
Accepted 25 October 2020

Keywords:

Questionnaire, endodontic, files, separation, instruments, fracture, removal, retrieval, survey.

ABSTRACT

Aim: To investigate the opinions and attitudes of general dental practitioners (GDPs) in Libya towards the separation of endodontic instruments.

Methodology: A pilot questionnaire was carried out on 20 GDPs to ensure that the questions were easily understood. The sample size comprised of 275 systematically selected GDPs, the questionnaire included both close-ended and partially closed-ended questions in four groups: demographics; a pattern of practice and experience of instrument fracture; management of fractured instruments and, finally, unsuccessful management of fractured instruments. Data were analyzed using the chi-square test at $P \leq 0.05$.

Results: The overall response rate was 97%. 90.2% of respondents had an experience of instrument fracture. The majority of respondents inspect the instrument before and during treatment. Only 4.9% of respondents reported that they would retrieve separated instruments located in the apical part of root canals. 43.6% of GDPs reported the use of the H-files Braiding technique for the removal of fractured instruments. Excessive removal of dentine was considered as the most common complication of the retrieval of fractured instruments (50.7%). 49.6% of respondents would prefer to leave the unsuccessfully removed file in the canal.

Conclusion: Separation of endodontic instruments is a procedural error that frequently occurs during endodontic treatment. The GDPs need to be familiar with the conservative techniques, which are available to retrieve separated instruments. All efforts should be made to upgrade clinicians' skills and knowledge with regards to the use and retrieval of endodontic instruments via hands-on and continuing education courses.

1. Introduction

The main objective of root canal treatment is complete debridement and shaping of the root canal system (Vertucci, 1984). However, various mishaps are frequently faced by GDPs on a daily basis (Yadav *et al*., 2012). One of those most challenging and unfortunate occurrences is the separation of endodontic instruments. This mishap acts as a blockage and may prevent achieving the objectives of endodontic treatment (Torbinejad & McDonald, 2009), precluding access to the apical part of the root canal and prevent instrumentation and obturation to the full working length. Consequently, the root canal treatment will be delayed and the outcome of the treatment will be affected (Triantafyllia *et al*., 2018). Earlier studies have reported a prevalence rate for the separated instrument ranging from 1% to 6% (Sjögren *et al*., 1990; Hu¨lsmann & Schinkel, 1999; Parashos *et al*., 2004, Spili *et al*., 2005; Di Fiore *et al*., 2006; Iqbal *et al*., 2006; Knowles *et al*., 2006; Wolcott *et al*., 2006). This unfortunate occurrence remains a frustrating situation for both GDPs and endodontists even with the advent of nickel-titanium alloy files and rotary instrumentation techniques. Many researchers reported a separation rate for nickel-titanium files reached up to 10% (Ramirez-Solomon *et al*., 1997; Baumann & Roth, 1999; Hu¨lsmann *et al*., 2003; Al-Fouzan 2003, Fishelberg *et al*., 2004; Ankrum *et al*., 2004; Di Fiore *et al*., 2006; Iqbal *et al*., 2006; Knowles *et al*., 2006; Wolcott *et al*., 2006; Wu *et al*. 2011).

In different countries, several surveys have been carried out to evaluate the incidence of instrument separation among the GDPs in different countries: Switzerland; Barbakow & Lutz (1997) reported an incidence of 76% of Light-Speed rotary instruments user, Australia; Parashos & Messer (2004) reported an incidence rate of 74% and in the UK, Madarati *et al.* (2008a) reported an incidence

2020 University of Benghazi. All rights reserved. ISSN 2663-1407; National Library of Libya, Legal number: 390/2018

of 89%. Several guidelines have been summarized by Grossman (1969) for the prevention of separated endodontic file which is mostly related to the operator, and include the following: instruments should be examined before and after use; instruments should not be used in dry canals; files should be used according to the manufacturer's instructions and finally, excessive forces should be avoided.

Complex anatomy, excessive pressure, and incorrect insertion angle were reported by Swiss dentists as the main causes of instrument separation (Barbakow & Lutz, 1997). It is well documented that the removal of separated instruments is strenuous, frustrating, time-consuming, and may lead to further complications. However, all attempts should be considered to remove them. Separated instruments remain an area of research for many investigators. While, some researchers investigated the different methods for the retrieval of separated instruments (Hu¨lsmann & Schinkel 1999; Ward *et al*., 2003a, b; Shen *et al*., 2004; Suter *et al*., 2005), others focused on the complications which might be associated with its retrieval (Ward *et al*., 2003 a, b; Souter & Messer,2005). Furthermore, the outcomes of endodontic treatment with retained separated instruments have been investigated by other authors (Spili *et al*., 2005). Nevertheless, limited data are available regarding the attitudes and experience of general dental practitioners with regards to the management of separated instruments. To date, there is no report on the attitude and opinions of Libyan GDPs towards the intracanal separation of endodontic instruments. Therefore, this study aimed to investigate the attitudes and opinions of GDPs in Libya towards the fracture of endodontic instruments and their management.

2. Materials and Methods

A survey of GDPs in the country of Libya was carried out regarding the experience of separated instruments while performing an endodontic treatment and their management. The methodology was described previously by Madarati *et al.* (2008 a, b). The correspondent author has been contacted for permission to use their questionnaire in the current study and he kindly agreed. A pilot self-administrated questionnaire was first carried out on 20 GDPs from different private sectors to ensure that the questions were easily understood. This provided several recommendations for improvement and clarity within the text, and these were subsequently incorporated into the final document. The sample size was calculated using a power calculation and is comprised of 275 GDPs working in the country of Libya.

This study requested information on the attitudes and experience of GDPs towards the separation of endodontic instruments and their management. The questionnaire comprised of 32 questions in two forms, closed and partially closed-ended questions that grouped into four groups:

- Demographics: four non-numbered questions (three closed-ended and one partially closed-ended).
- The pattern of practice and experience of instruments fracture: 18 questions (12 closed-ended and six partially closed-ended).
- Management of fractured instruments: six questions (four closed-ended and two partially closed-ended).
- Unsuccessful management of fractured instruments: four closed-ended questions.

Data were entered into SPSS 20 for Windows and were analyzed using chi-squared tests at the $P< 0.05$ level of significance.

3. Results

Of the original sample size of 275 distributed questionnaires, 266 were returned completed. Seven GDPs did not return the questionnaire and two GDPs returned the incomplete filled questionnaire. Those unreturned and incomplete filled questionnaires were not calculated in the final response and considered as non-eligible cases according to an evidence-based study on the response and nonresponse bias in oral health surveys carried out by Locker in 2000. Thus, the response rate achieved in this study was 97%.

3.1 Demographic data: *Respondents sex, year of graduation, and pattern of work*

56.4% of respondents were male and 43.6% were female [P=0.037]. There was a significant difference between males and females with regard to the experience of file fracture with the highest incidence among males [χ^2= 7.8, df=1, P=0.005]. The year of graduation ranged from 1983-2016 (Fig. 1). The proportion of GDPs graduating between 2001-2016 (68.1%) was significantly higher than those who graduated before 2001(31.9%) [P<0.001].

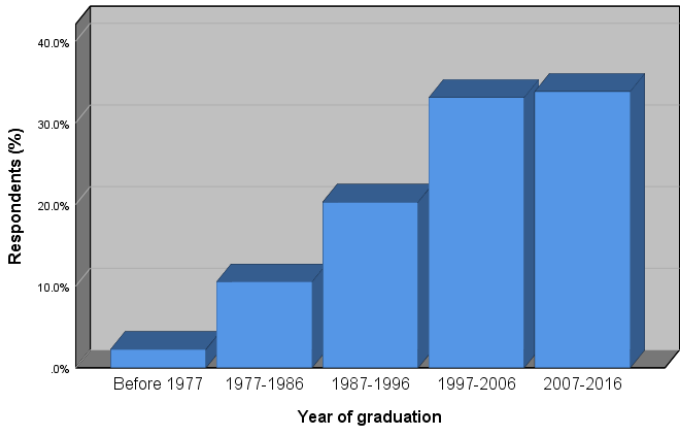

Fig. 1. Respondents details regarding years of graduation

The majority of the respondents (91.7%) worked in private practices. There was a statistically significant difference between private workers and non-private workers [χ^2=409.29, df=2, P< 0.001].

3.2. The number of cases per week

The highest proportion of GDPs performed 6-10 cases per week (58.6%) (Fig. 2). There was a statistically significant difference among respondents with regards to the number of cases per week [χ^2=178.48, df=3, P<0.001]. As the number of cases increases the experience of file separation is increased (Fig. 3).

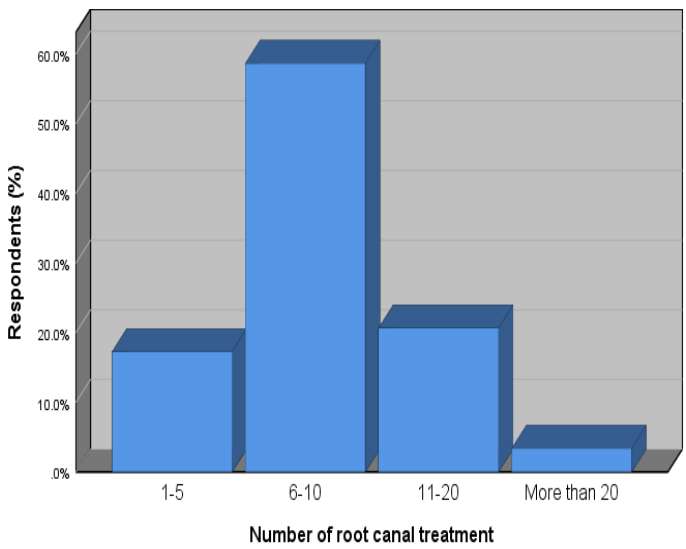

Fig. 2. The percentages of root canals treatment performed by GDPs per week

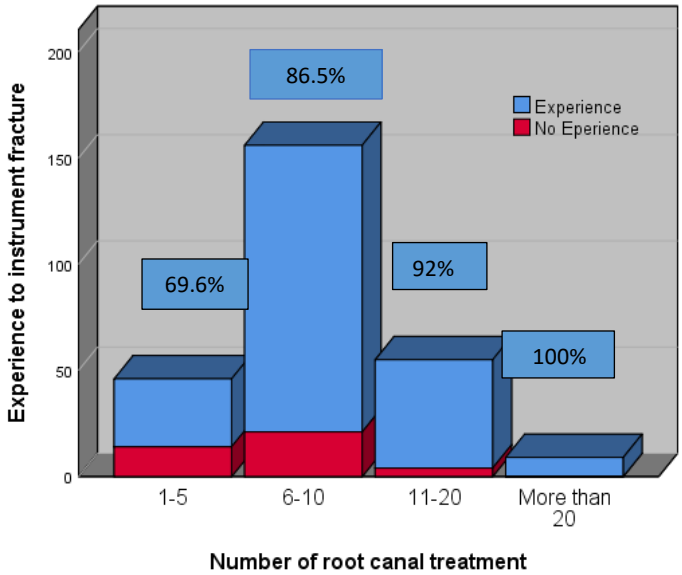

Fig. 3. Experience of instruments fracture according to the number of cases performed per week

3.3 The technique of canal preparation and the use of hand instruments

More than half of respondents reported the use of a crown-down technique (53.4%) and 42.9% of respondents reported the use of step-back. 3.8 % of respondents reported using other techniques. There was a statistically significant difference among the participants with regards to the techniques of preparation [χ^2= 109, df=2, *P*<0.001]. While 44% of respondents reported the use of stainless steel (SS) files,27.8%, reported the use of nickel titanium (Ni-Ti) files. 28.2% of respondents reported using both types of files (SS and Ni-Ti). There was a statistically significant difference among the respondents with regards to the types of files used [χ^2=13.5, df=2, *P*= 0.001].

3.4 Use of a rotary system and its common type

The higher proportion of respondents (62.4%) used rotary systems for cleaning and shaping of the root canals. The proportion was statistically significant [χ^2=16.37, df=1, *P*<0.001]. A higher proportion of males (85.3%) reported the use of rotary systems compared with females (32.8%) and that is highly significant [χ^2=77.06, df=1, *P*<0.001]. While 39.2% of participants would prefer to use the M3-Pro Gold rotary system, 28.9% and 21.1% would prefer to use Race and ProTaper systems respectively. Only Nine respondents (3.4%) reported the use of the ProFile system. Moreover, the use of more than one rotary system was reported by six individuals (Fig. 4). There was statistically significant differences between the respondents with regards to the type of rotary system used [χ^2=118.81, df=5, *P*<0.001].

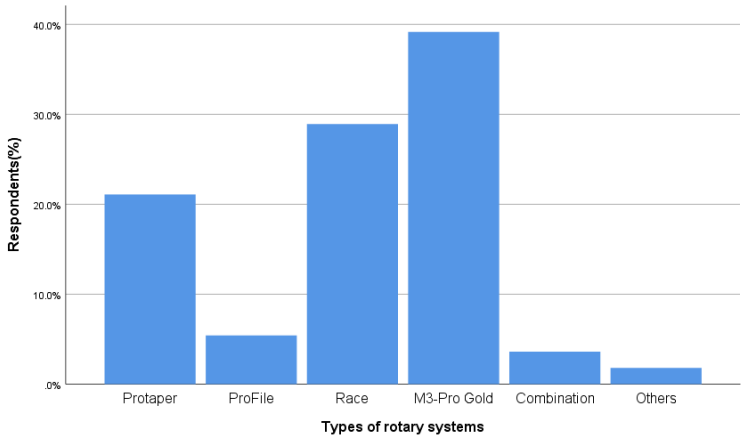

Fig. 4. Respondents details regarding the preferred rotary systems

3.5 Hand-on courses on the use of rotary systems and the retrieval of separated instruments

A significantly higher proportion of GDPs had not attended either courses on the use of rotary instrument (71.4%) or the retrieval of separated instruments (95.5%) and both showed a significant proportion [χ^2= 48.85, df=1, *P*<0.001] [χ^2=220, df=1, *P*<0.001] respectively.

3.6 Patterns of files examination

Participants were asked about the patterns of file examination. They were provided with multiple closed-ended responses. The majority of respondents (84.6%) indicated that they examined instruments before treatment. All responses were statistically significant (Table 1).

Table 1

Patterns of the examination of endodontic files (More than one answer was allowed)

Patterns of files inspection	Frequency	%	χ2	df	*P*-value
Before treatment	255	84.6	127.27	1	<0.001
Regularly during treatment	161	60.5	11.78	1	0.001
After treatment	99	37.2	17.38	1	<0.001
Occasionally during treatment	93	35	24.06	1	<0.001
Before sterilization	61	22.9	77.95	1	<0.001
After sterilization	34	12.8	147.38	1	<0.001
Combination	27	10.2	168.96	1	<0.001

3.7 Instruments examination via magnification

Three options were given to the respondents (always, sometimes, and never). Only 2.3% of respondents reported they always use magnification in forms of dental loupes to examine the endodontic instrument (Fig. 5). There was a statistically significant difference between the respondents [χ^2=290, df=2, *P*<0.001]. None of the respondents reported the use of a dental operating microscope.

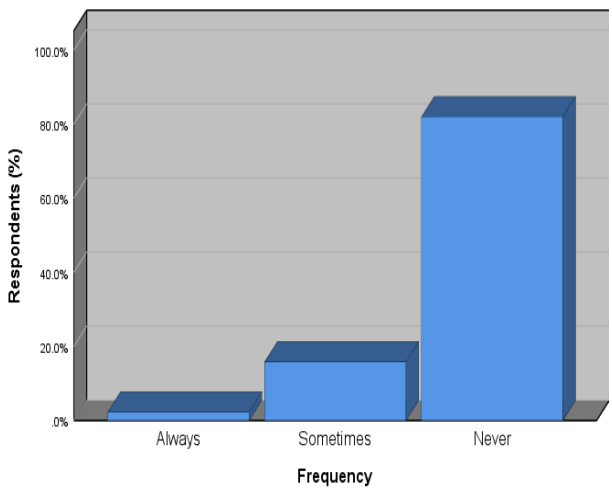

Fig. 5. Frequency of file examination via magnification

3.8 Policies of discarding endodontic files

The highest proportion of respondents (70.3%) discarded files after naked deformation followed by 25.6% of participants who discarded the endodontic files after a certain number of uses. Only six participants reported the use of magnification for the decision on discarding endodontic files. The differences between all policies of file discarding were statistically significant [χ^2=330.30, df=3, P<0.001] (Table 2).

Table 2

The discarding policies of endodontic files among participants.

Participants	Polices				
	after a number of uses	after naked deformation	after magnified deformation	after fracture of the file	**Total**
Frequency	69	188	6	3	266
Percentages	26	71	2	1	100

3.9 The contributing factors for instrument separation

Participants were requested to grade the number of factors from the greatest to lowest important, and the most important factor, which might contribute to instrument fracture. Five categories of contributing factors were provided. The highest proportion of respondents (46.6%) believed that the *operator* was the most important factor contributing to instrument fracture, followed by root canal anatomy (37.6%). The third factor was related to *instrument design* which has been reported by 20% of respondents. The last and least factors were related to *manufacturing* and *environmental factors*, which were reported by 3.8% and 4.5% respectively. The difference between the participants in their point of view regarding the contributing factors was statistically significant [χ^2=222.09, df=4, P<0.001].

3.10 Respondents experience towards file/instrument separation; a number of separated files per week and their types

Table 3 illustrates the participant's experience towards file separation and also the number and types of separated files. Overall, 90.2% of participants had the experience of instrument separation during root canal treatment. Only 9.8% reported no experience of separation of endodontic files. There was a statistically significant difference among the respondents [χ^2=172.16, df=1, P<0.001]. There was also a statistically significant difference regarding the experience of file separation with both the year of graduation [χ^2=25.07, df=4, P< 0.001] and the type of work [χ^2=44.37, df=2, P<0.001]. Almost half of GDPs (49.6%) had experience from 1 to 5 fracture instruments. 36.1 % reported a fracture incidence of more than 10 files. There was a statistically significant difference among the participants with regards to the number of fracture files [χ^2=50.73, df= 2, P<0.001]. While more than half of respondents (54.1%) had the experience of hand instruments fracture, 41.1% of respondents reported the experience of rotary instrument fracture. There was a statistically significant difference among respondents with regards to the types of fractured instruments [χ^2=105.95, df=2, P<0.001].

3.11 Fractured instrument (teeth involved and the location, length, and size of fractured instruments)

The majority of respondents (79.7%) reported that fractured instruments are more likely to occur more in molar teeth (Fig. 6), the difference between groups of teeth was statistically significant [χ^2=263.85, df=2, P <0.001]. Table 4 summarizes the incidence of fractured instruments according to location, length, and size of fractured instruments within the canals. Significantly, the highest proportion of respondents (74.4%) reported that most instruments fractured at the apical one-third of the root canal followed by the middle third of the root canal system which was reported by 20.3% of respondents. These differences were statistically significant [χ^2=211.25, df=2, P<0.001]. Significantly, the highest proportion of respondents (78.2%) reported that most of the instrument fragments were short [up to 3mm] followed by those who reported that most of the instrument fragments were medium in length [>3and <5 mm] (17.3%). These differences were statistically significant [χ^2= 247.42, df=2, P<0.001]. The small size fragment represents the highest proportion of instrument separation which was reported by 56% of respondents followed by median size (41.4%). There was a statistically significant difference with regards to the size of separated instruments among respondents [χ^2=124.6, df= 2, P<0.001].

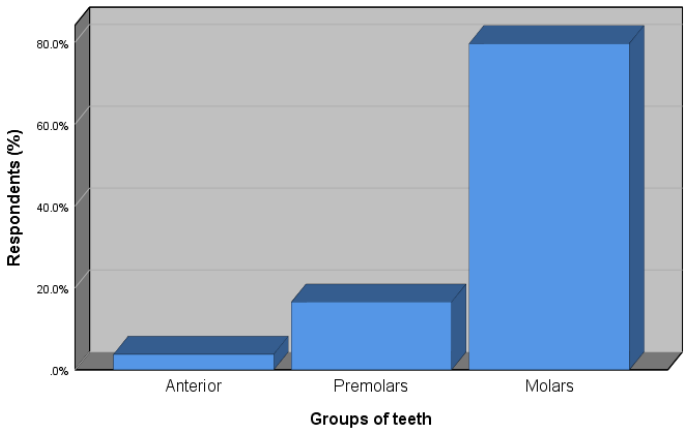

Fig. 6: The incidence of separated instruments in different groups of teeth.

Table 3

Respondents fracture experience, number and the types of fractured instruments

Experience of file separation	%	Number of separated files	%	Types of separated files	%
		1-5	49.6	Hand file	54.1
Yes	85.3	6-10	14.3	Rotary file	41.1
No	14.7	>10	36.1	Both	4.5
Total	**100**	**Total**	**100**	**Total**	**100**

Table 4

The incidence of location, length, and size of fractured instruments.

Details	Location of fracture file			Length of fracture file			Size of fracture file		
	Apical	Middle	Coronal	≤3	> 3 to < 5	>5	Small	Medium	large
%	74.4	20.3	5.3	78.2	17.3	4.5	56.4	41.4	2.3
χ^2	211.25			247.42			124.63		
P value	<0.001			<0.001			<0.001		

3.12 Management of fractured instruments at different locations inside the root canal

Table 5 demonstrates the different types of management of fractured instruments in different parts of the root canal.

Coronal third: The majority of respondents (80.1%) reported that they would try to retrieve the separated instruments located within the coronal third. 14.3% of respondents reported that they bypass the fragment. Only five respondents (1.9%) would prefer to refer such cases to endodontists. These differences were statistically significant [χ^2=439.83, df=3, *P*<0.001].

Middle third: The highest proportion of respondents (44.4%) would try to bypass the fragments located within the middle third of the root canal system. 33.8% of respondents reported that they would try to retrieve the fragments. While 2.3% of respondents would extract the tooth, 11.3% would leave the fragment and continue treatment with follow up. These differences were statistically significant [χ^2=257.759, df=5, *P*< 0.001].

Apical third: The vast majority of respondents (63.5%) would leave the fragment in the canal and continue treatment and follow up the cases. 11.3% of respondents reported that they would extract the tooth. The minority of respondents (4.9%) reported that they would retrieve the fractured instrument. These differences were statistically significant [χ^2=319.30, df=4, *P*<0.001].

Table 5

Management of separated instrument at different locations inside the root canal(%)

Type of management	Location of the fragment within the root canal system		
	Coronal third	Middle third	Apical third
Retrieve	80.1	33.8	4.9
Bypass	14.3	44.4	12
Leave and continue treatment	3.8	11.3	63.5
Perform surgery	0	3	0
Extract	0	2.3	11.3
Refer to endodontist	1.9	5.3	8.3

3.13 Number of visits and time needed for retrieving the separated files in a single visit

The proportion of respondents who used to manage fractured instruments in multi-visits (64.7%) was significantly greater than respondents who adopted a single-visit approach (35.3%). There was a statistically significant difference between both management approaches [χ^2=22.87, df=1, *P*<0.001]. More than 50% of respondents reported that they need up to 30 minutes to retrieve separated instruments in a single visit. Only 1.5% of respondents would spend more than 60 minutes. There was a statistically significant difference among the respondents with regards to the time needed for the single visit [χ^2=189.15, df=3, *P* <0.001] (Table 6).

Table 6

Number of visits and time required to retrieve the fractured instrument

Number of visits	Time			
Single visit	Up to 30 min	Up to 45 min	Up to 60 min	More than 60 min
	53.4%	36.8	8.3	1.5
	35.3%			
Multiple visits	64.7%			

3.14 Techniques for retrieving separated instruments

43.6% reported applying the H-files Braiding technique for the removal of separated instruments, 36.6% prefer to use ultrasonic devices for the removal of separated instruments. Only 2.3% of respondents reported the use of the Masserann technique. Finally, 17.3% reported the use of other techniques. The difference among the respondents was statistically significant [χ^2=189.15, df=3, *P*<0.001].

3.15 Use of Magnification while retrieving separated instrument and the type of magnification

Most of the respondents (85.7%) did not use magnification while removing fractured instruments. There was a statistically significant difference among respondents [χ^2=135.71, *P*<0.001]. All of the respondents (100%) who reported the use of magnification reported the use of dental loupes. None of the respondents reported the use of a dental operating microscope.

3.16 Experience of complications while retrieving separated instruments:

51.1% of respondents reported that they experienced complications during the removal of separated instruments. The difference among the respondents was not statistically significant (χ^2=0.135, df=1, *P*=0.713). The most common complication was excessive dentine removal which has been reported by 59.6% of respondents. The difference among the participants was statistically significant (χ^2=4.971, df=1, *P*=0.026). The second most common complication was the fracture of another instrument (44.1%). The latter was not statistically significant [χ^2= 1.882, df=1, P= 0.17]. Root perforation was reported by 39% of respondents. The latter was statistically significant among the respondents [χ^2=6.618, df= 1, *P*= 0.010]. Only 12.5% of respondents reported extrusion of fragment apically. The difference among the respondents was statistically significant [χ^2=76.50, df=1, *P*<0.001]. Multi-complications were reported by 27.2% of the participants. The latter was statistically significant [χ^2=28.26, df= 1, *P*<0.001].

3.17 The success rate of separated instruments removal according to a location within the root canals:

Respondents were asked to report an estimated success rate for the removal of separated instruments. Four categories of success rate (1-25%%, 26-50%, 51-75%, 76-100%) were considered (Table 7). Respondents reported significantly different estimated success rates for removal of the separated instrument within each group according to the location of fractured fragments within the root canal system. A higher success rate was reported in removing fragments located at the coronal level, and the poorest success rate

was reported with the fractured instrument at the apical third. The success rate among the respondents was statistically significant in all locations [P< 0.001] (Table 7).

Table 7

The success rate for the removal of fractured instruments from the coronal, middle, and apical third of the root canal. *The values presented in parentheses are percentages.

Success rate	Location within the root canal		
	Coronal	Middle	Apical
Poor (1-25%)	40 (15)	118 (44.4)	230 (86.5)
Fair (26-50%)	47 (17.7)	104 (42.9)	20(7.5)
Good (51-75%)	84 (31.6)	29 (10.9)	14(5.3)
Very good (76-100%)	95 (35.7)	15 (5.6)	2 (0.8)
Chi square (χ^2)	33.098	122.06	538.51
P value	<0.001	<0.001	<0.001

3.18 Unsuccessful management of separated files (*Types of files, teeth position, places in the root canals, and treatment approaches*):

Types of files: 37.6% reported unsuccessful experiences with the management of fractured instruments for all types of files. While 30.8% of respondents reported the unsuccessful management of rotary files, 20.3% reported the unsuccessful management of separated stainless-steel files. The least unsuccessful management involved the Ni-Ti hand file (11.3%). There was a statistically significant differences among respondents with regards to the unsuccessful management of all files (χ^2= 42.87, df= 3, P<0.001).

Teeth position: The majority of respondents (83.5%) reported that molar teeth were the most common teeth for the unsuccessful management of separated files. Premolars and anterior teeth were reported by respondents as unsuccessfully managed with proportions of 10.5% and 6% respectively. The difference among the GDPs was statistically significant (χ^2=301.56, df=2, P<0.001).

Places in the root canals: 69.9% reported that the apical one third as the highest incidence of unsuccessful management of separated files. The separated instruments at the middle and coronal one-third of the root canal were unsuccessfully treated by 21% and 9% of respondents respectively (χ^2=166.045, df=2, P<0.001).

Treatment approaches: Almost half of the respondents (49.6%) reported filling the root canal up to the broken piece (Fig. 7). The minority of respondents (8.3% and 9.8%) tended to perform apical surgery and tooth extraction respectively. 32.3% preferred to refer their cases to specialists. There was a statistically significant difference among the respondents with regards to the treatment approaches (χ^2=124.67, df=3, P<0.001).

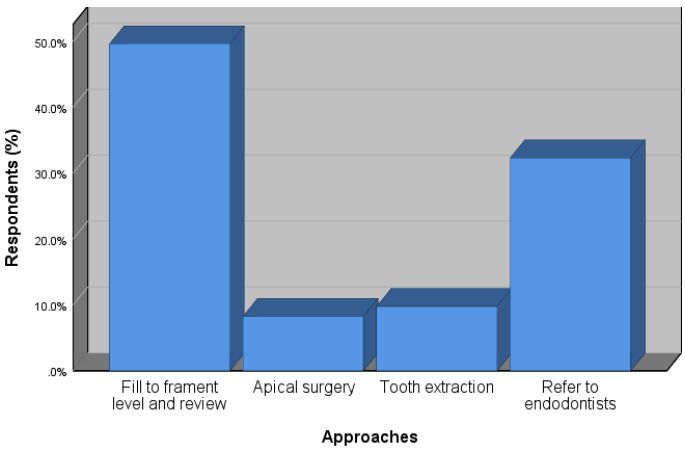

Fig. 7. Different management approaches for unsuccessful retrieval of separated instruments.

4. Discussion

Separation of endodontic instruments is one of the unexpected and unpredicted endodontic mishaps that general dental practitioners may face during root canal treatment (Hulsmann & Schinkel 1999). Despite advances in the development of endodontic instruments, instrument fracture is remaining a big issue. The latter was investigated by many studies (Hulsmann & Schinkel 1999; Parashos *et al.*, 2004; Spili *et al.*, 2005), other studies addressed the attitudes and opinions of GDPs towards the fracture of endodontic instruments (Barbakow & Lutz, 1997; Parashos & Messer, 2004; Madarati *et al.*, 2008a, b).

In this study, it was decided to investigate the attitudes and opinions of GDPs in Libya regarding the separation of endodontic instruments, it was believed that would be appropriate owing to lack of knowledge in this area. The majority of the respondents graduated between 2001-2016 and that was significant compared with the early graduates ranged from 1983-2000. The majority of GDPs work in private practice and perform from 6-10 cases per week. There was a correlation between the practitioner's clinical experience and the separation of endodontic instruments.

Disappointedly, in the current study, the majority of GDPs had not attended further training courses either on the use of rotary instruments (71.4%) or the retrieval of separated instruments (95.5%). This is in disagreement with Madarati and colleagues (2008a) who reported that the majority of respondents (79.3%) had at least attended one hands-on course on the use of rotary systems. It could be argued that the mandatory continuing professional development (CPD) courses in the UK encourage the UK GDPs to attend such important courses as part of CPD which is required for them as a condition for their registration with the GDC (General Dental Council, 2020) and enhances their skills and knowledge. The importance of continuing education courses in endodontics has been highlighted by Barbakow and Lutz, (1997). The latter enables the GDPs to upgrade their skills and knowledge in the new areas which belong to endodontic treatment such as new instruments and techniques especially those related to the use of new rotary files and conservative techniques for the retrieval of separated instruments.

In the current study, it was reported that 62.4% of respondents used the rotary systems. The latter was comparable with Madarati *et al.* (2008a) [65%] and Parashos & Messer (2004) [58%]. A lower proportion was reported by Barbakow & Lutz (1997) [22%].

The current survey reported that GDPs were commonly aware of the need to examine endodontic instruments before use. Most of the GDPs (84.6%) reported examining their instrument before treatment and during treatment (60.5%). This is in agreement with Madarati *et al.* (2008a) who showed that the majority of their respondents reported examining their instruments before (77%) and during (67.8%) treatment. Moreover, the authors reported that 55% of their respondents followed an effective combined approach for the examination of endodontic instruments, which include the examination of the instrument before and during the endodontic treatment. The current study reported the same strategy with only 27% of GDPs.

Numerous circumstances have significantly benefited from the usage of magnification in endodontics. The latter would enhance the vision and illumination and can facilitate the retrieval of silver-point, separated instrument, and fractured post (Nehme 2001; Terauchi *et al.*, 2006; Gencoglu &Helvacioglu, 2009). Moreover, many researchers have highlighted the importance of magnification in the detection of minute deformity in the instrument (Kuhn *et al.*, 2001; Svec & Powers, 2002; Peng *et al.*, 2005). The use of a dental operating microscope permits working under bright illumination and magnification (Plotino *et al.*, 2007) and create direct visualization of the deeply situated separated instruments within the root canals in the area where the naked eye cannot detect them (Shiyakov & Vasileva, 2014). Moreover, they limit the hazard of the perforation owing to the unnecessary removal of dentin (Spili *et al.*,

2005; Iqbal *et al*., 2006). The use of a dental operating microscope facilitates the easy and successful removal of separated instruments (Cujé, 2010). In the current study, only 2.3% of respondents reported that they always use magnification to examine the endodontic instruments. The proportion of respondents who always use magnification was significantly lower than non-users. It could be argued that the cost of the magnification devices limits their use among the GDPs.

The strategy of discarding the used endodontic instruments was also investigated in this study. The majority of respondents (70.7%) discard their instruments after naked eye visualisation of any deformities. While single-use of the endodontic instrument was not reported in the current study, another study showed that 45% of respondents would discard the endodontic files after single-use (Madarati *et al*., 2008a). The importance of single-use endodontic instruments was highlighted by Kazim (2017), who reported that single-use would minimize the risk of instrument fracture and cross infection. It could be argued that the cost of endodontic files especially the rotary files forced the clinicians to use them for multiple cases. The GDPs should be aware of the time and fees which may be needed to retrieve the broken files.

In this study, the GDPs were aware of the factors which may expose the instrument to fracture inside the root canals. The operator's skills and proficiency have been ranked as the utmost significant among the contributing factors for instrument fracture (Parashos *et al*., 2004; Cheung, 2009). The latter was also reported in the current study in which the respondents classified the operators as the most important factor which contribute to instrument fracture. Moreover, the risk of instrument fracture seems to be increased in cases with complex root canal anatomy (Peters *et al*., 2003). In this study, the canal anatomy represents the second most important factor that exposes the instrument to fracture. The latter was in agreement with other previous studies (Parashos*etal*.,2004, Madarati *et al*., 2008b). On the other hand, Barbakow & Lutz (1997) showed that canal morphology was the least considered factor (15%). Over usage, excessive pressure, and root canal anatomy were reported as the most important factors for instrument fracture with a proportion of 62%, 43%, and 36% respectively (Parashos & Messer, 2004). In this study, factors related to the manufacturer (3.8%) and environment (4.5%) were considered as the least important factors. This is in agreement with another study (Madarati *et al.,* 2008b).

In the current study, the vast majority of respondents (90.2%) had experienced endodontic instruments fracture. The latter was higher than reported in previous research: 85.1% (Madarati *et al*., 2008a); 76% (Barbakow & Lutz, 1997); 74% (Parashos & Messer, 2004). It could be explained by the lack of continuing education courses in endodontics especially those related to the use of rotary nickel-titanium files. In this study, the highest proportion of respondents (49.6%) reported the experience of file separation ranged from 1 to 5 files followed by 36.1% of respondents who reported experience of more than 10 files. Furthermore, there was a correlation between the number of fractured files and the number of cases per week. This is in agreement with other researchers (Madarati *et al*., 2008a). In this study, separation of endodontic files was reported with both hand and rotary files with a percentage of 54.1% and 41.1% respectively.

In the current study, the majority of respondents reported that the highest incidence of file separation occurred whilst treating molar teeth (79.7%). This is in agreement with previous studies (Iqbal *et al*., 2006; Wu *et al*., 2011; Ungerechts *et al*., 2014; Wang *et al*., 2014). Mesio-buccal root canals of both maxillary (Iqbal *et al*., 2006; Wu *et al*., 2011) and mandibular molars (Hulsmann 1999; Wards *et al*., 2003a; Iqbal *et al*., 2006; Wu *et al*., 2011) were reported as the most common sites for instruments separation. These reported findings could be attributed to the complexity, curvature of the root canal, and the uneven root canal walls of molar teeth (Kessler 1983; Lim & Stock, 1987). In this study, the incidence of instrument fracture in the apical part of the canal was reported by the majority of respondents (74.5%) as the most commonplace. The latter was comparable with Madarati *et al.* (2008a) who reported an incidence of 84.4%.

Whenever an instrument separates in the canal, a decision has to be made to either leave, bypass, or remove; the selection depends on the assessment of the possible benefit versus the risk of complication of its retrieval (McGuigan *et al*., 2013). One of the key factors that influence the decision in the management of separated instruments is the location of fractured instruments inside the root canal. Besides, the experience of general dental practitioner plays an important role in the management of separated instruments at various locations inside the root canal. Madarati *et al.* (2013) stated three attempts for dealing with separated instruments: *Retrieval* as a first option if the fragment is accessible, low risk of further complications, the tooth is strategically important, the instrument separated at an early stage of canal instrumentation and the clinician is well trained; *bypassing* is considered as the second approach if the fragment separated at an early stage of the canal instrumentation and is unapproachable in a strategically important tooth, and the practitioner has enough experience; Finally, Leaving the fragment in situ as last conservative approach when attempts at removal and bypassing of the fragment are unsuccessful. In the current study, it was obvious that the more apically placed instrument, the less chance of its retrieval. Only 4.9% of the GDPs reported an attempt to retrieve the instrument from the apical one-third of the canal. Conversely, the majority of respondents (80.1%) reported their ability to retrieve the fractured instruments from the coronal one-third of the root canal. The latter was in agreement with another study (Madarati *et al*., 2008b) who reported that the majority of the respondents (86.9%) would prefer to retrieve the broken instruments if they were situated in the coronal part. Authors have reported that almost half of the respondents would prefer to retrieve the fractured instruments if they were located in the middle part of the root canal. This was not the case in this study in which 44.4% of respondents would prefer to bypass them. The latter could be attributed to the lack of skills, knowledge, experience and continuing education courses on the retrieval of broken instruments. Those gaps decrease the ability of clinicians to visualise the separated instruments and retrieve them. It was also noted that the GDPs were not keen to refer difficult cases to endodontists and tried to manage them. This finding was not very promising for the success of the treatment owing to the importance of the experience and education in the management of difficult and more challenging cases. McGuigan *et al.* (2013) highlighted the importance of the referral to an endodontist if the retrieval of the separated instrument was considered as the most suitable option for the success of treatment. In this study the referral according to the location within the canal was as follows; apically (8.3%), medially (5.3%), and coronally (1.9%). Low incidence of referral to endodontists was also reported by Madarati *et al.* (2008b) with a proportion of 21.3% 14.9% and 2.3% for apically, medially, and coronally placed separated instruments respectively.

The selection of retrieval techniques for separated instruments varies from one practitioner to another. In the current study, 43.6% would prefer to use the H-files Braiding technique [HFBT] to retrieve the broken instruments from the root canals. The latter might be due to the high cost of different instrument retrieval systems such as; instrument removal system, ultrasonic, and also Masserann kit. The HFBT is considered as a simple and more economic technique to retrieve the broken instruments. Another study (Madarati *et al*., 2008b) reported only 8.8% of practitioners would prefer this technique to retrieve broken files. "Ultrasonic" was considered as a conservative and safe technique for the retrieval of separated instruments (Harleen *et al*., 2015) and also very effective (Nagai *et al*. 1986; Ward, 2003) especially in the most challenging places (apical, curved and narrow canals) (Shen & colleagues, 2004). Many researchers (Nagai *et al*., 1989; Hülsmann *et al*., 1999; Suter *et al*., 2005; Alomairy, 2009; Cujé *et al*., 2010; Ward *et al*., 2013b) recommend the use of ultrasonic de-

vices in conjunction with magnification owing to their conservative effectiveness in the removal of separated instruments from the canals. In the current study, 36.6% of respondents reported the use of ultrasonic devices to retrieve the separated instruments, a higher proportion (75.8%) was reported by Madarati *et al*., (2008b), the authors believed that dental education affects the practitioner's choice for such a technique.

Only a minority of the respondents (2.3%) reported the use of the Masserann technique. The latter was reported as a successful device in the management of the removal of separated instruments, its low use among the respondents could be attributed to its cost and availability. Masserann techniques have been used for 40 years and different success rates were reported with the range of 25–55%. (Masserann 1966; Feldman *et al*., 1974; Fors & Berg, 1983; Hu¨lsmann 1990; Okiji 2003). Excessive removal of dentine was highlighted by Yoldas *et al*. (2004) as one of the drawbacks of Masserann technique, which may lead to root perforation. Madarati *et al*. (2008b) reported the use of Masserann technique among 38.6% of respondents. Only 17% of respondents stated that they would try more than one technique to retrieve the separated instruments. Applying more than one technique to retrieve the separated instrument was recommended by many authors in order to obtain the best management outcomes (Hülsmann 1993; Ruddle, 2004; Shen *et al*., 2004; Suter *et al*., 2005; Terauchi *et al*., 2007). Madarati *et al*. (2008b) reported that 63.4% of respondents would prefer to apply more than one technique to remove the fractured instruments.

The use of a dental operating microscope has been recommended for the successful retrieval of separated instruments by many authors (Ward 2003; Ward *et al*., 2003a, b; Wei *et al*., 2004; Suter *et al*., 2005). However, this study showed that only 14.3% of respondents reported the use of magnification and none of them reported the use of a dental operating microscope. All emphasis should be applied to encourage the GDPs to use the dental operating microscope. This will subsequently minimize the complications during the retrieval of separated instruments.

Many studies reported several complications while retrieving separated instruments (Ward *et al*., 2003a, b; Suter *et al*., 2005; Madarati *et al*., 2008b). In the current study, 51.1% of the respondents reported that they had faced a complication while retrieving the separated instruments. The main complication was the excessive removal of dentine, which was reported by 50.7% of respondents. The latter may be owing to the need for the removal of more dentine in order to visualise and hold the instrument and move it coronally, which was in agreement with Madarati *et al.* (2008b). In 2006, Parashos and Messer highlighted the importance of direct vision and straight-line access as important factors that should be considered while treating a case with a separate instrument. The latter could also justify the dentine loss while the general dental practitioner was attempting to retrieve the fractured instruments. Moreover, other studies (Souter & Messer 2005; Madarati *et al*., 2008 a, b) recommended bypassing the fractured instrument especially those located in the apical third of root canals and those located at severely curved canals (Souyave *et al*., 1985; Hülsmann, 1994). The authors justified their recommendation by the possibility of excessive removal of dentine.

The second reported complication in this study was the fracture of other instruments which had been reported by 40.4% of the GDPs. Moreover, root perforation is also reported by 39% of respondents. The GDPs should be aware of the canal morphology to minimize the chance of root perforation and also avoid stress while performing a file braid technique to remove the fractured file and use the magnification to visualize the condition of the file which will be used to retrieve the fractured instruments.

Whilst the majority of respondents (78.3%) reported a retrieval success rate of over 50% when a fractured instrument was located in the coronal one-third of the root canal, 40.8% did so when it was located in the middle third. The lowest figure of over 50% success rate was reported when the fragment was located in the apical third (6.6%). These results were consistent with those reported in previous studies. Hülsmann & Schinkel (1999) found the lowest success rate of 59% when fractured instruments were removed from the apical one-third compared with middle and coronal thirds (69% and 100% respectively).

A success rate of over 50% for the retrieval of separated instruments in the coronal part of the root canal was reported by 67.3 % of the respondents. Conversely, a very low success rate of over 50% was reported by the respondents when they try to retrieve the instrument from the middle (16.5%) and apical one third (5.5%) of root canals. It could be argued that might be owing to inadequate practitioner's skills experience and also the unavailability of the retrieval systems such as the instrument removal system and Masserann kit. Moreover, the separated instrument in the apical part of the tooth is often unapproachable and more likely to bind to the walls of the root canal. The finding of this study was in agreement with other studies which have been conducted in different countries; in the UK, Madarati and colleagues (2008b) found that 78.3% of respondents showed a success rate of instrument retrieval of over 50% when the separated instrument was located in the coronal part of the root canal and lower success rate of over 50% was reported by respondents when they try to retrieve the separated instrument from the middle (40.8%) and apical (6.6%) part of the root canal; in Germany, Hülsmann & Schinkel (1999) reported success rate of 100%, 69% and 59% when the separated instruments were retrieved from the coronal, middle and apical one-third of the root canal respectively; in Australia, Souter & Messer (2005) reported a success rate of 24% when the instrument was located in the apical part of the root canal.

In the current study, the maximum failure rate for the management of separated instruments was reported in the apical part (69.9%) of the root canal and molar teeth (83.5%). The latter was in agreement with other authors (Madarati, 2008b) who reported a proportional failure rate of 88.4% in molar teeth and 84.8% in the apical one third. Many studies found that the success rate will be decreased when the separated instrument lies beyond the canal curvature (Hülsmann & Schinkel 1999; Ward *et al*.,2003a,b; Shen *et al*., 2004; Souter & Messer, 2005; Suter *et al*., 2005). Those studies support the findings of this study. The current study showed that 37.6% of the respondents reported the unsuccessful management of separated files (*Stainless-steel, Nickel-Titanium hand, and rotary*). The fractured rotary files represent the highest proportion (62.4%) of unsuccessful management compared with separated stainless-steel files. The latter might be owing to the inadequate training courses with different rotary systems and also might be due to the cost-effectiveness as practitioners used the rotary files multiple times.

Respondents in this study were also asked to indicate their treatment approach in the case of unsuccessful broken file management. It was reported that almost half of the respondents (49.6%) indicated that they would fill the canal up to the broken file fragment. Other studies (Madarati *et al*., 2008b; Parashos & Messser, 2009) reported a significantly higher proportion of GDPs (82.9%, 79% respectively) would prefer to leave the fractured segment in the canal and follow-up their patients. It was believed that the treatment will be successful even with the separated instrument remaining in the canal (Spili *et al*., 2005). However, other authors suggested that the prognosis may eventually depend on what stage of canal preparation the separation occurred, which reflects the degree of microbial control within the canal (Spili *et al*., 2005).

Referral to an endodontist specialist was another treatment approach for the management of failed instrument retrieval. The removal of fractured instruments necessitates a higher level of technical skills, especially when retrieving separated instruments which are located in curved root canals. Considering the risks, it is crucial that clinicians can identify their limitations and consider referring their difficult cases to specialists whenever needed. The latter was considered as a first treatment approach according to Madarati *et al*. (2013) especially in the absence of retrieval instruments and with unskilled practitioners.

The General Dental Council of the UK (2020) states: 'If you are not confident to provide the treatment you must refer the patient to an appropriately trained colleague'.

In the current study, 32.3% of respondents would prefer to refer their difficult cases to specialists. Apical surgery or extraction was reported as the least used treatment option for unsuccessful instrument retrieval (8.3%, 9.8% respectively). This is in agreement with another study (Madarati *et al*., 2008b).

5. Conclusions

A high proportion of GDPs had experienced instrument separation. The operator factor was considered as the most important factor that contributes to instrument separation. The majority of GDPs utilized the file braiding technique to retrieve the separated instruments. Curved root canals and the apical part of root canals were considered as the most difficult and challenging places for instrument retrieval. Molar teeth were the most common teeth in which instrument separation may occur. Excessive removal of sound dentine was reported as the main complication of the management of separated instruments. Further training courses should be provided to the GDPs on the different conservative approaches for instrument retrieval. However, GDPs showed a conservative approach towards the unsuccessful management of separated instruments by leaving them in the root canals. The lack for the use of the dental operating microscope in the dental clinics highlights the importance of providing educational courses on the benefits of its use in endodontic treatment, especially for challenging cases such as retrieving separated instruments in the difficult area such as the apical part of the root canal and also in more severely curved canals.

References

Alomairy, K. H. (2009) 'Evaluating two techniques on removal of fractured rotary nickel-titanium endodontic instruments from root canals; an in vitro study', Journal of *Endodontics*, 35, pp. 559–562.

Al-Fouzan, K.S. (2003) 'Incidence of rotary ProFile instrument fracture and the potential for bypassing in vivo', *International Endodontic Journal*, 36, pp. 864–867.

Ankrum, M.T., Hartwell, G.R., Truitt, J.E. (2004) 'K3 Endo, ProTaper, and ProFile systems: breakage and distortion in severely curved roots of molars', *Journal of Endodontics*, 30, pp. 234–237.

Barbakow, F., Lutz, F. (1997) 'The 'Light speed' preparation technique evaluated by Swiss clinicians after attending continuing education courses', *International Endodontic Journal*, 30, pp.46–50.

Baumann, M.A., Roth, A. (1999) 'Effect of experience on quality of canal preparation with rotary nickel-titanium files', *Oral Surgery Oral Medicine Oral Pathology Oral Radiology and Endodontics*, 88, pp. 714–718.

Cheung, G.S. (2009) 'Instrument fracture: mechanisms, removal of fragments, and clinical outcomes', *Endodontic Topics*, 16, pp. 1–26.

Cujé, J., Bargholz, C., Hülsmann, M. (2010) 'The outcome of retained instrument removal in a specialist practice', *International Endodontic Journal*, 43, pp. 545-554.

Di Fiore, P.M., Genov, K.A., Komaroff, E., Li, Y., Lin, L. (2006) 'Nickel-titanium rotary instrument fracture: a clinical practice assessment', *International Endodontic Journal*, 39, pp. 700–708.

Feldman, G., Solomon, C., Notaro, P., Moskowitz, E. (1974) 'Retrieving broken endodontic instruments', *Journal of the American Dental Association*, 88, pp. 588–591.

Fishelberg, G., Pawluk, J.W. (2004) 'Nickel-titanium rotary-file canal preparation and intracanal file separation', *Compendium of Continuing Education in Dentistry*, 25, pp. 17–18; 20–22; 24, quiz 25, 47.

Harleen, C., Manoj, K.S., Subhash, C. (2015) 'Ultrasonics: A Novel Approach for Retrieval of Separated Instruments case report', *Journal of Clinical and Diagnostic Research*, 9(1), pp. 18-20.

Hülsmann, M., Schinkel, I. (1999) 'Influence of several factors on the success or failure of removal of fractured instruments from the root canal', *Endodontics & Dental Traumatology*, 15, pp. 252–258.

Hülsmann, M. (1990) 'Removal of silver cones and fractured instruments using the Canal Finder System', *Journal of Endodontics*, 16, pp. 596–600.

Hülsmann, M. (1993) 'Methods for removing metal obstructions from the root canal', *Endodontics & Dental Traumatology*, 9, pp. 223–237.

Hülsmann, M. (1994) 'Removal of fractured instruments using a combined automated/ultrasonic

Technique', *Journal of Endodontics*, 20, pp. 144–147.

Hülsmann, M., Herbst, U., Schäfers, F. (2003) 'Comparative study of root-canal preparation using

Light speed and Quantec SC rotary NiTi instruments', *International Endodontic Journal*, 36, pp. 748–756.

General Dental Council:https://www.dentistry.co.uk/2018/06/19/referral-dilemmas-root canal-treatment/, accessed online on 17/05/2020

Gencoglu, N., Helvacioglu, D. (2009) 'Comparison of the different techniques to remove fractured endodontic instruments from root canal systems', *European Journal of Dentistry*, 3, pp.90–95.

Grossman, L. (1969) 'Guidelines for the prevention of fracture of root canal instruments', *Oral Surgery Oral Medicine and oral Pathology*, 28 (5), 746-752.

Iqbal, M.K., Kohli, M.R., Kim, J.S. (2006) 'A retrospective clinical study of incidence of root canal Instrument separation in an endodontics graduate program: a PennEndo database study', *Journal of Endodontics*, 32, pp.1048–1052.

Kazim, M. (2017) 'Single Use of Endodontic Instruments K', *Ecronicon Dental Science*, 8, 1, pp. 1-7.

Kessler, J.R., Peters, D.D., Lorton, L. (1983) 'Comparison of the relative risk of molar root perforations using various endodontic instrumentation techniques', *Journal of Endodontics*,9, 439–447.

Knowles, K.I., Hammond, N.B., Biggs, S.G., Ibarrola, J.L. (2006) 'Incidence of instrument separation using Light Speed rotary instruments', *Journal of Endodontics*, 32, pp. 14–16.

Kuhn, G., Tavernier, B., Jordan, L. (2001) 'Influence of structure on nickel-titanium endodontic instruments failure', *Journal of Endodontics*, 27, pp. 516-520.

Lim, S.S., Stock, C.J. (1987) 'The risk of perforation in the curved canal: anticurvature filing compared with the step-back technique', *International Endodontic Journal*, 20, pp. 33–39.

Locker, D. (2000) 'Response and non-response bias in oral health surveys', *Journal of Public Health Dentistry*, 60, pp. 72–81.

Madarati, A.A., Watts, D.C., Qualtrough, A.J.E. (2008a) 'Opinions and attitudes of endodontists and general dental practitioners in the UK towards the intra-canal fracture of endodontic instruments: part I', *International Endodontic Journal*, 41, pp. 693–701.

Madarati, A.A., Watts, D.C.& Qualtrough, A.J.E.(2008b)'Opinions and attitudes of endodontists and general dental practitioners in the UK towards the intracanal fracture of endodontic instruments. Part 2', *International Endodontic Journal*, 41, pp. 1079–1087.

Madarati, A.A., Hunter, M.J., Dummer, P.M.H. (2013) 'Management of Intracanal Separated instruments' *Journal of Endodontics*, 39(5), pp. 569-581.

Masserann, J. (1966) 'The extraction of posts broken deeply in the roots', *Actual Odontostomatol*, 75, pp. 329–342.

McGuigan, M.B., Louca, C., Duncan, H.F. (2013) 'Clinical decision-making after endodontic instrument fracture', *British Dental Journal*, 214(8), pp. 395-400.

Nagai,O., Yani, N., Kayaba, Y., Kodama, S., Osada,T. (1986)'Ultrasonic removal of broken instruments in root canals', *International Endodontic Journal*, 19, pp. 298–304.

Nehme, W.B. (2001) 'Elimination of intracanal metallic obstructions by abrasion using an operational microscope and ultrasonics', *Journal of Endodontics*, 27, pp. 365–367.

Okiji, T. (2003) 'Modified usage of the Masserann kit for removing intracanal broken instruments', *Journal of Endodontics*, 29, pp. 466–467.

Parashos, P., Gordon, I., Messer, H.H. (2004) 'Factors influencing defects of rotary nickel-titanium endodontic instruments after clinical use', *Journal of Endodontics*, 30, pp. 722–725.

Parashos, P., Messer, H.H. (2004) 'Questionnaire survey on the use of rotary nickel–titanium endodontic instruments by Australian dentists', *International Endodontic Journal*, 37, pp.249-259.

Peng, B., Shen, Y., Cheung, G. S., Xia, T. J. (2005) 'Defects in ProTaper S1 instruments after clinical use: longitudinal examination', *International Endodontic Journal*, 38, pp. 550-555.

Peter, P. & Harold, H. M. (2006)'Rotary NiTi Instrument Fracture and its Consequences', *Journal of Endodontics*, 32(11), pp. 1031-1043.

Plotino, G., Pameijer, C.H., Maria G. N., Somma F (2007) 'Ultrasonic in endodontics: A review of the literature', Journal of Endodontics, 33, pp. 81-95.

Ramirez-Solomon, M., Soler-Bientz, R., de la Garza-Gonzalez, R., Palacios-Garza, C.M. (1997) 'Incidence of LightSpeed separation and the potential for bypassing', *Journal of Endodontics*, 23, pp. 586–587.

Ruddle, C.J. (2004) 'Nonsurgical retreatment', *Journal of Endodontics*, 30, pp. 827–845.

Shen, Y., Peng, B., Cheung, G.S. (2004) 'Factors associated with the removal of fractured NiTi instruments from root canal systems', Oral *Surgery, Oral Medicine Oral Pathology, Oral Radiology and Endodontics*, 98, pp. 605–610.

Shiyakov, K.K., Vasileva, R.I. (2014) 'Success for removing or bypassing instruments fractured beyond the root canal curve-45 clinical cases', *Journal of IMAB Annual Proceeding (Scientific Papers)*, 20(3), pp. 567-571.

Sjo¨gren, U., Hagglund, B., Sundqvist, G., Wing, K. (1990) 'Factors affecting the long-term results of endodontic treatment', *Journal of Endodontics*, 16, pp. 498–504.

Souter, N.J., Messer, H.H. (2005) 'Complications associated with fractured file removal using an ultrasonic technique', *Journal of Endodontics*, 31, pp. 450–452.

Souyave, L.C., Inglis, A.T., Alcalay, M. (1985) 'Removal of fractured endodontic instruments using ultrasonics', *British Dental Journal*, 159, pp. 251–253.

Spili, P., Parashos, P., Messer, H.H. (2005) 'The impact of instrument fracture on outcome of endodontic treatment', *Journal of Endodontics*, 31, pp. 845–850.

Suter, B., Lussi, A., Sequeira, P. (2005),'Probability of removing fractured instruments from root canals', *International Endodontic Journal*, 38, pp. 112–123.

Svec, T.A., Power, J.M. (2002) 'The deterioration of rotary nickel titanium files under controlled conditions', *Journal of Endodontics*, 28, pp. 105-107.

Terauchi, Y., O'Leary L, Suda, H. (2006) 'Removal of separated files from root canals with a new file-removal system: Case reports', *Journal of Endodontics*, 32, pp. 789–797.

Terauchi, Y., O'Leary, L., Kikuchi, I.Kikuchi, L., Asanagi, M. , Yoshioka,T. , Kobayashi,C. , Suda, H. (2007) 'Evaluation of the efficiency of a new file removal system in comparison with two conventional systems', *Journal of Endodontics*, 33, pp. 585–588.

Torbinejad, M. & McDonald, N.J. (2002) 'Endodontic surgery'. In: Torabinejad, M., Walton, R.E. eds. Endodontics principles and practice. 4th Edt., St Louis.

Triantafyllia, V., Maryam, E.C., Kleoniki, L.(2018)'Separated instrument in endodontics: Frequency, Treatment and Prognosis',Balkan Journal of Dental Medicine, 22, pp.123-132.

Ungerechts, C., Bårdsen, A., Fristad, I. (2014) 'Instrument fracture in root canals-where, why, when and what? A study from a student clinic', *International Endodontic Journal*, 47(2), pp. 183-190.

Vertucci, F.J. (1984) 'Root canal anatomy of the human permanent teeth', *Oral Surgery Oral Medicine and Oral Pathology*, 58(5), pp. 589-599.

Wang, N.N., Ge, J.Y., Xie, S.J., Chen, G., Zhu, M. (2014) 'Analysis of Mtwo rotary instrument separation during endodontic therapy: a retrospective clinical study', *Cell Biochem Biophys*, 70(2), pp. 1091-1095.

Ward, J.R. (2003) 'The use of an ultrasonic technique to remove a fractured rotary nickel-titanium instrument from the apical third of a curved root canal', *Australian Endodontic Journal*, 29, pp. 25–30.

Ward, J.R., Parashos, P., Messer, H.H. (2003a) 'Evaluation of an ultrasonic technique to remove fractured rotary nickel titanium endodontic instruments from root canals: an experimental study', *Journal of Endodontics*, 29, pp. 756–763.

Ward, J.R., Parashos, P., Messer, H.H. (2003b) 'Evaluation of an ultrasonic technique to remove fractured rotary nickel titanium endodontic instruments from root canals: clinical cases, *Journal of Endodontics*', 29, pp. 764–767.

Wang, N.N., Ge, J.Y., Xie, S.J., Chen, G., Zhu, M. (2014) 'Analysis of two rotary instrument separation during endodontic therapy: a retrospective clinical study', *Cell Biochem Biophy*, 70(2), pp. 1091-1095.

Wei, X., Ling, J.Q., Gao, Y., Huang, X.Y., Li, X.X. (2004) 'Management of intracanal separated instruments with the microsonic technique and its clinical outcome', *Zhonghua Kou Qiang Yi Xue Za Zhi (Chinese Journal of Stomatology)*, 39, pp. 379–381.

Wolcott, S., Wolcott, J., Ishley, D., Kennedy,W., Johnson, S. , Minnich, S., Meyers, J. (2006) 'Separation incidence of protaper rotary instruments: a large cohort clinical evaluation', *Journal of Endodontics*, 32, pp. 1139–1141.

Wu, J., Lei, G., Yan, M., Yu,Y. , Yu,J. , Zhang, G. (2011) 'Instrument separation analysis of multi-used ProTaper Universal rotary system during root canal therapy', *Journal of Endodontics*, 37, pp. 758–763.

Yadav, R.K., Chand, S., Verma, P., Chandra, A., Tikku, A.P., Wadhwani, K.K. (2012) 'Clinical negligence or endodontic mishaps: a surgeons Dilemma', *National journal of maxillofacial*, 3(1), pp. 87-90.

Yoldas, O., Oztunc, H., Tinaz, C., Alparslan, N. (2004) 'Perforation risks associated with the use of Masserann endodontic kit drills in mandibular molars', *Oral Surgery, Oral Medicine, Oral Pathology, Oral Radiology and Endodontics*, 97, pp. 513–517.