Libyan Journal of Science & Technology 14:1 (2022) 21-27

Faculty of Science - University of Benghazi

Libyan Journal of Science & Technology

journal home page: www.sc.uob.edu.ly/pages/page/77

# Morphological study of the vertebral column and thoracic cage of the Rüppell's fox (*Vulpes rueppellii*) in the Benghazi area.

**Abdulgader K. Youssef *, Ahmed W. Ahmed and Neema A. Darnawi**

*Department of Zoology, Faculty of Science, University of Benghazi, P.O. Box: 9480, Benghazi, Libya*

## Highlights

- **The results of this paper fill a wide gap of information in the axial skeleton of *V. rueppelli* fox that was not available in the past.**
- **This study exclusively shows the articulation and the precise structures of the vertebrae, sternum, and ribs that are included in the thoracic cage of the mentioned fox.**

ARTICLE INFO

*Article history:*

Received 13 November 2021
Revised 16 March 2022
Accepted 17 March 2022

*Keywords:*

*V. rueppelli*, Benghazi, fox, vertebrae, ribs, sternum.

**Address of correspondence:*

*E-mail address:* Abdulgaderkhalifa4@gmail.com

A. K. Youssef

ABSTRACT

The vertebral column and thoracic cage of a Rüppell's fox from the Benghazi area were morphologically investigated and described in this study. The fox's vertebral formula was C7, T13, L7, S3, Ca22. In the middle of the pedicle, the fourth vertebra of the normal cervical vertebrae has a paddle-shaped process. The paired accessory processes of the thoracic vertebrae are found posteriorly beside the neural arch of the vertebrae. The dorsal side of the seventh vertebra of the caudal vertebrae has a narrow groove. There were a total of thirteen pairs of ribs. The first nine ribs were sternal, while the final three were asternal. The last rib was floating, and the sternum was made up of nine sternebrae arranged in cylindrical shape.

## 1. Introduction

The notochord is the primary axial skeleton in most tetrapods, and it is then replaced by the vertebral column. The vertebral column in Mammals is usually divided into five parts (Webster, 1974), and the thoracic cage is made up of a specific pair of ribs, with a total of 25 separate bones in the sternum. The rib cage's functions include protecting vital organs such as the heart and lungs (Folkens *et al.,* 2012).

Canidae is one of the most well-known families of carnivores found throughout most of the world. As a canine, foxes, dholes, dingoes, wolves, jackals, coyotes and various dogs inhabit every continent except Antarctica (Sillero-Zubiri *et al.,* 2004). Despite the foxes' wide range, little is known about the species, which the International Union for Conservation of Nature lists as data-deficient (IUCN 2006).

Ellerman and Morrison-Scolt (1966) described some subspecies externally (size and color), but the observations show that there was a lot of variation between these specimens (Hüfnagl, 1972; Rosevear, 1974; Qumsiyeh, 1996). Furthermore, the following are some geographical distributions of some species that appear to be the most prevalent in the countries mentioned (Wozencraft, 2005): *V. r. rueppellii* (Egypt and Sudan), *V. r. caesia* (northwest Africa and Western Sahara), *V. r. cyrenaica* (including *V. r. cufrana*) (Libya, southwestern Egypt, and extreme north-western Sudan), *V. r. somaliae* (Eritrea and Somalia), *V. r. sabaea* (Middle East and Arabic (Baluchistan).

The Crab-eating fox has seven cervical vertebrae that are larger than the thirteen thoracic and seven lumbar vertebrae that decrease in size from anterior to posterior. The sacrum is made up of two fused sacral vertebrae that are about twenty to twenty-one caudal vertebrae (Barisson *et al*., 2012). The crab-eating fox has seven cervical, thirteen thoracic, and seven lumbar vertebrae, similar to the domestic dog (König and Liebich, 2002; Dyce *et al*., 2010). Alar notch and transverse foramen have been observed in the wolf and fox (Girgin *et al*., 1988), hyena (Tecirlioglu, 1983), mink (Dursun and Tipirdamaz, 1989), jackal (Gultekin and Ucar, 1980), and otter (Yilmaz *et al*., 2000). According to Barisson *et al*. (2012), the crab-eating fox's caudal vertebrae are fully developed in the anterior region, with transverse processes visible in the first five caudal vertebrae. Furthermore, they demonstrated three types of thirteen pairs of strongly curved thick ribs in their study: nine pairs of true ribs, two false pairs, and two floating pairs.

© 2022 University of Benghazi. All rights reserved. ISSN: Online 2663-1407, Print 2663-1393; National Library of Libya, Legal number: 390/2018

Many different vertebral formulae have been reported in carnivores, including: C7, T13-16, L4-6, S2-4, Ca15-25 in Mustelidae (Grasse, 1967); C7, T13, L7, S3, Ca in the wolf and the fox (Girgin *et al*., 1988); C7, T13, L7, S3, Ca in the fox and jackal (Gultekin and Ucar, 1980); C7, T14, L6, S3, Ca in the hyena (Tecirlioglu, 1983); in the mink C7, T14, L7, S3, Ca15-18 (Dursun and Tipirdamaz, 1989); and in otters C7, T14, L6, S3, Ca18 (Yilmaz *et al*., 2000).

Ribs in Carnivora include nine sternal and four asternal ribs in the fox and jackal (Gultekin and Ucar, 1980); six sternal and seven asternal and one floating in the mink (Dursun and Tipirdamaz, 1989); nine sternal and four asternal and one floating in the dog (Evans and Christensen, 1979); and nine sternal and four asternal and one floating in the otter (Yilmaz *et al*., 2000).

The sternum had five sternebrae in the mink (Dursun and Tipirdamaz, 1989), eight in the wolf and fox (Girgin *et al*., 1988), eight or nine in the dog (Evans and Christensen, 1979), and nine in the otter (Yilmaz *et al*., 2000).

Because there is little information about foxes in Libya, this species (Rüppell's fox) was chosen to study the morphology and size of different bones in its vertebral column, ribs, and sternum, thereby contributing to filling a knowledge gap in this part of the fox skeleton.

## 2. Materials and methods

Ten fox specimens were collected in the Benghazi area, including one from Taknis, two from Tokra, one from Sidi Khalifa, two from Nawaguea, two from Jardena, one from Soltan, and one from Al Mabni. Each fox was assigned a code that is an abbreviation of the region in which it was discovered. The foxes were discovered dead on the roads, where they had been hit by cars, as well as on farms and coastal beaches. According to Stephen and Nawrocki (1997), two methods were used to obtain the bones by removing the muscles and skin:

The first method involved burying the specimen as soon as it was collected. Calcium oxide (CaO) was used to speed up the decomposition process. Depending on the working conditions, the period of burial varied from specimen to specimen. This method was used on the majority of the species.

After extracting the specimens, the only organs discovered were the bones, skin, and fur residues. To obtain only the bone, the skin was carefully removed with hands and forceps. The bones were then cleaned with hot water to remove dirt, soil, and skin residue. Sometimes the skin is strongly attached to the bones, so it was soaked in ammonia solution (NH3) and then cleaned with forceps and a toothbrush to be removed without damaging the bones.

The second method involved dissecting the corpse immediately after obtaining it, removing the internal organs, skinning the skin, and removing all of the muscles with anatomy tools and ammonia solution. After cleaning, the bones are gray due to the length of the burial period or the effect of cleaning materials on them, and to bleach them, they are sprayed with hydrogen peroxide (H2O2) and left to dry slowly in a dark place, or by soaking in potassium hydroxide (KOH) for a few minutes and then letting it dry slowly under the sun. To study the components of the postcranial bones, the organs were disassembled by distilling some droplets from the ammonia solution in between the vertebrae and other bones, leaving it for several minutes, then carefully separating the bones from each other.

The bones were stored in special tubes and boxes containing naphthalene (C10H8) as a preservative, and each bone was assigned a symbol. The images of bones were captured using a variety of cameras, and the views were altered using the paint program. The morphological description was applied to the various vertebrae of the vertebral column, the ribs, and the sternum.

## 3. Results

The vertebral column (Fig. 1) is the second part of the axial skeleton behind the skull, and it is made up of the following vertebrae:

**I. Cervical vertebrae**: There are seven cervical vertebrae (Fig. 2), which are as follows: A. The Atlas (Fig. 3) is the first cervical vertebra, a butterfly-shaped butterfly with broad and flat transverse processes. It has a wide neural foramen and a narrow neural spine and centrum. The two anterior articular facets are more concave than the two posterior ones, and each facet has two foramina. B. The Axis (Fig. 4) is the second cervical vertebra with a well-developed neural spine and an anterior process opposite the ventral odontoid process, which has two lateral convexity facets. Postzygapophyses with lower facets are present, as is a wide flat centrum between two short transverse processes. C. Normal cervicals (Fig. 5) are the remaining five cervical vertebrae, which are distinguished by the gradually increasing size of the neural spine from first to fifth. Their pre- and post-zygapophyses each have two upper and lower facets. From the first to the fifth transverse process, the length gradually decreased. In the middle of the pedicle, the fourth vertebra has a paddle-shaped process. Except for the last cervical vertebra, the transverse foramen is present in all cervical vertebrae.

**II. Thoracic vertebrae** (Fig. 6): There are thirteen thoracic vertebrae, each with a long pointed neural spine. These spines gradually shrank from anterior to posterior until they were reduced in the last three vertebrae; their length also shifted from posterior to anterior in the last three vertebrae. Except for the first, the postzygapophyses are more prominent and closer together (Fig. 7). The prezygapophyses of the last three vertebrae are separated by a deep pair of concave facets (Fig. 8). A pair of accessory processes located posteriorly beside the neural arch of vertebrae. Upper and lower facets are found at the anterior and posterior bases of each spine. The diapophysis and parapophysis can be found on either side of the short transverse process and the centrum, respectively.

**III. Lumbar vertebrae**: There are seven large lumbar vertebrae (Fig. 9), each with a short neural spine that is craniodorsally directed and paired laterally transverse processes that gradually increase in length from the first to the last ones. The transverse processes are cranioventrally directed. The more prominent prezygapophyses have deep concave facets in between them to receive the lower facets of the postzygapophyses (Fig. 10).

**IV. Sacral vertebrae**: The sacrum is made up of three sacral vertebrae that have fused together (Fig. 11). The first sacral vertebrae is the largest, with a broad anterior centrum and a wide neural canal. Its prezygapophyses are characterized by lateral articulating facets and broad, short transverse processes. The third vertebra has paired short, thin backward-directed transverse processes and a posterior narrow centrum. The neural spines of the vertebrae are not fused together.

**V. Caudal vertebrae**: There are twenty-two caudal vertebrae (Fig. 12) that are fully developed in the anterior region, each with a short neural spine, and the transverse process is more visible in the front vertebrae from the first to the seventh and is caudally directed (Fig. 13). From the fifth to the last vertebra, the body of the vertebra becomes more elongated and cylindrical. From the seventh vertebra, the neural foramen and posterior processes vanish and are replaced by postzygapophyses until the seventeenth vertebra, where they remain only as a centrum. There is a

pair ventral process under the anterior centrum from the third to the end of the vertebrae, which is absent in the posterior centrum (Fig. 14). These processes resulted in a triangular haemal foramen in the fourth and fifth caudal vertebrae (Fig. 15A). In addition, there is only one narrow groove on the dorsal side of the seventh vertebra (Fig. 15B).

The thoracic cage is described morphologically. This cage is related latero-ventrally to the thoracic vertebrae and is made up of the following bones:

**I. Ribs** (Fig. 16): There are thirteen pairs of ribs, each with a dorsal tuberculum and a ventral capitulum. In the anterior ribs, the two heads are more prominent. The rib shaft is flat in the first five ribs and cylindric in the remaining ribs (Fig. 17). The longest pairs are the eighth, while the shortest is the first. There are nine pairs of ribs, which have costal cartilages articulated to the sternum and are also known as true ribs. The next three pairs are false because they are not directly articulated to the sternum. Because the last pair does not articulate, either directly or indirectly, to the sternum, they are known as the floating pair.

**II. Sternum**: A ventral structure of the thoracic region that serves as the foundation for the cartilage portion of the ribs. It is made up of nine small cylindrical sternebrae with a narrow anterior end and a broad posterior end. The first is the manubrium, and the last is the xiphisternum, which takes the shape of an anchor and ends with xiphoid cartilage (Fig. 16).

Articulation between vertebrae: The vertebrae are articulated together by interlocking the upper facets of prezygapophyses with the lower facets of postzygapophyses, as well as the presence of intervertebral cartilage disks between the vertebrae (Fig. 1). The Atlas' anterior articular facets articulate with the occipital condyles. The Axis's odontoid process fits into the Atlas's ring, and the facets processes of the odontoid articulate with the Atlas's posterior articular facets. Only the intervertebral disks articulate from the sixth caudal vertebra. The concavity, convexity, and dorsal and ventral processes of vertebrae are regions that connect muscles and control the angular movement of the vertebral column.

Articulation between the thoracic cage: In thoracic vertebrae, the diapophyses from the transverse process and the parapophyses of the centrum are articulated with the upper tuberculum and lower capitulum of the ribs, respectively (Fig. 16).

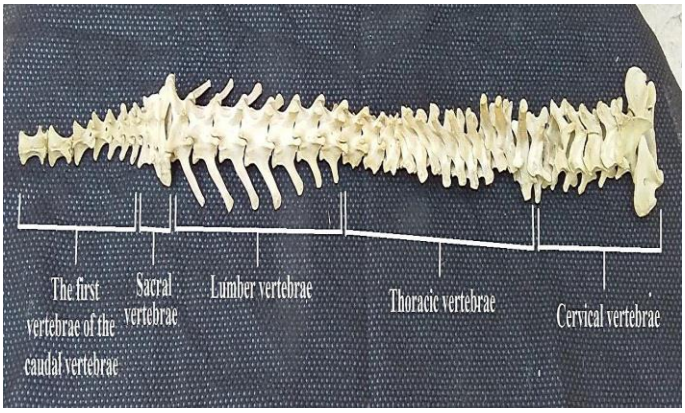


**Fig. 1.** Dorsal view of the vertebral column.

**Fig. 2.** Cervical vertebrae: A. Dorsal view. B. Lateral view.

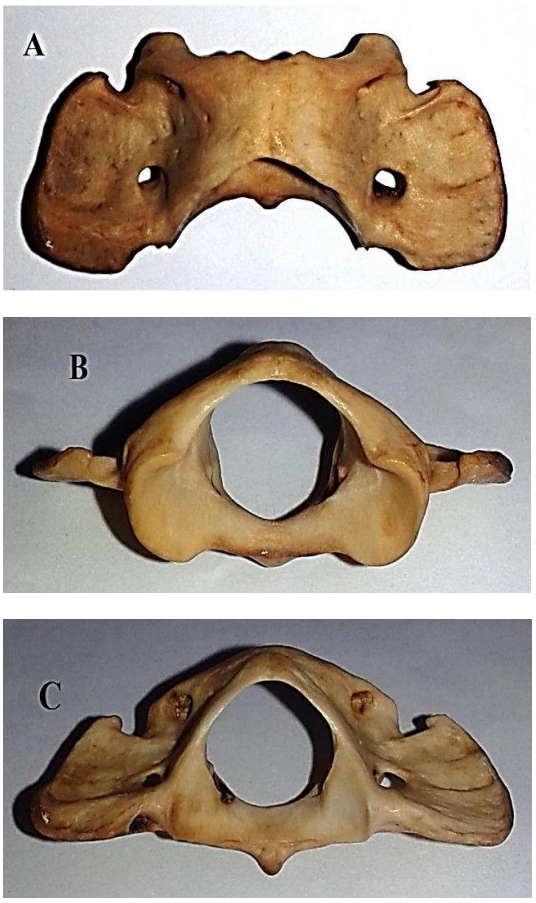


**Fig. 3.** Atlas: A. Dorsal view. B. Anterior view. C. Posterior view.

**Fig.4.** Axis: A. Lateral view. B. Anterior view. C. Posterior view.

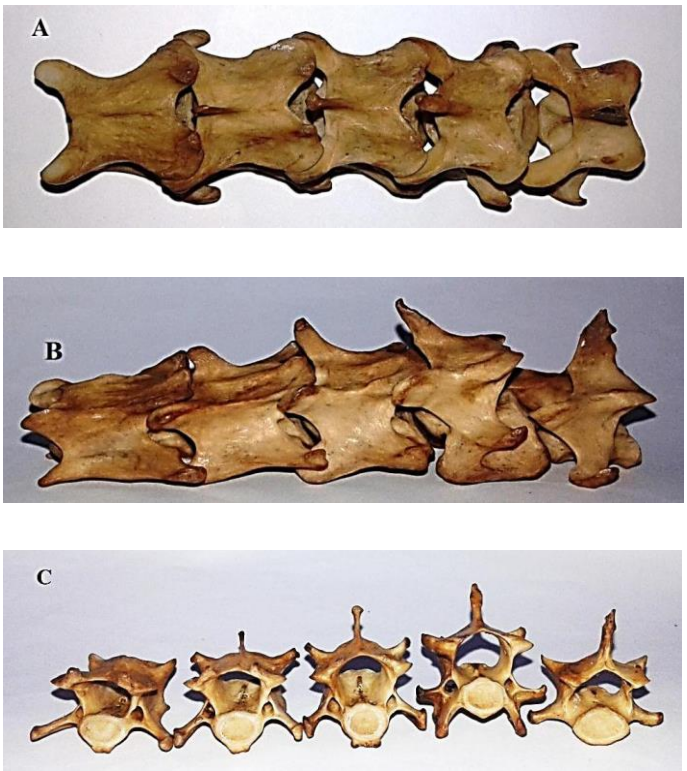


**Fig. 5.** Normal cervicals: A. Dorsal view. B. Lateral view. C. Posterior view.

**Fig. 6.** Lateral view of thoracic vertebrae.

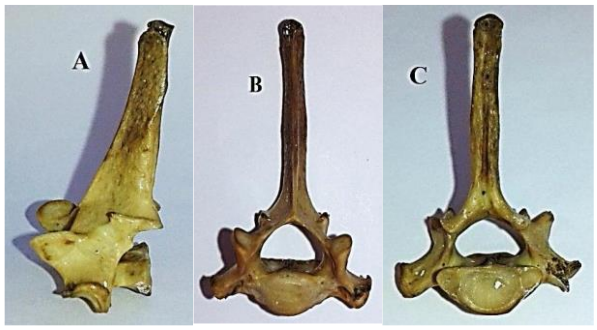


**Fig. 7.** The first thoracic vertebra: A. Lateral view. B. Anterior view. C. Posterior view.

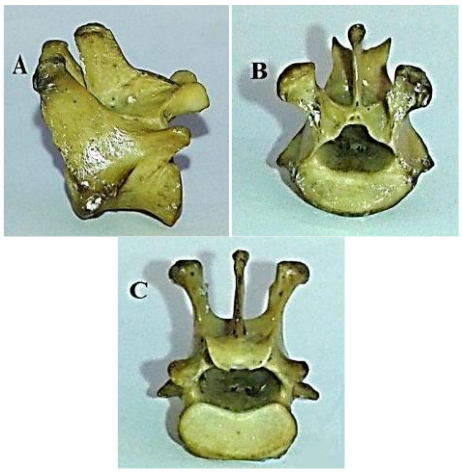


**Fig. 8.** The last thoracic vertebra: A. Lateral view. B. Anterior view. C. Posterior view.

**Fig. 9.** Lumbar vertebrae: A. Dorsal view. B. Lateral view.

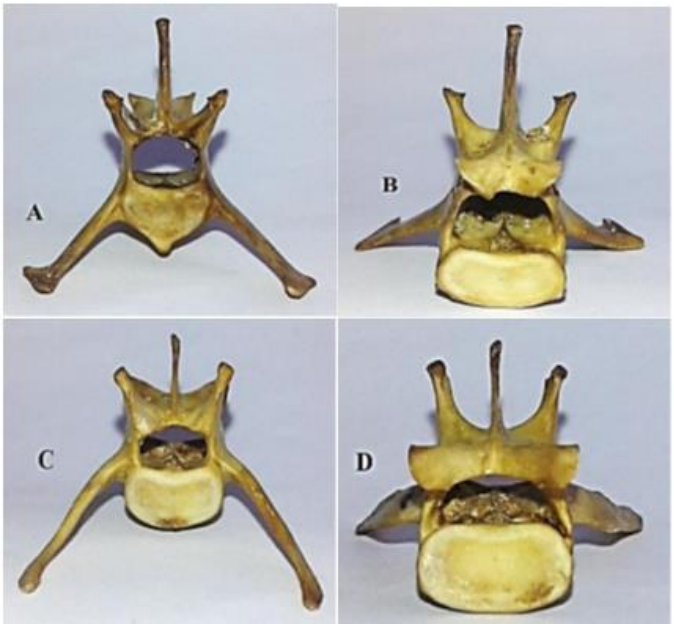


**Fig. 10.** Views of lumber vertebrae: A. Anterior- B. Posterior-fourth vertebra. C. Anterior. D. Posterior- last vertebra.

**Fig. 11.** Sacrum: A. Dorsal view. B. Lateral view. C. Anterior view.

**Fig. 12.** Dorsal view of caudal vertebrae.

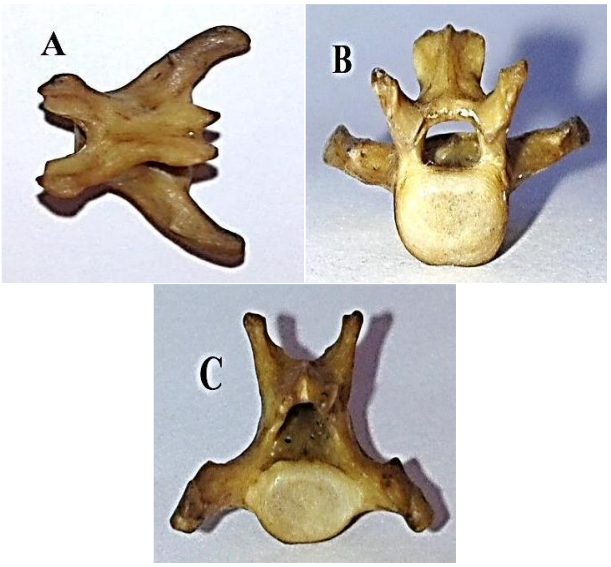


**Fig. 13.** The second caudal vertebra: A. Dorsal view. B. Anterior view. C. Posterior view.

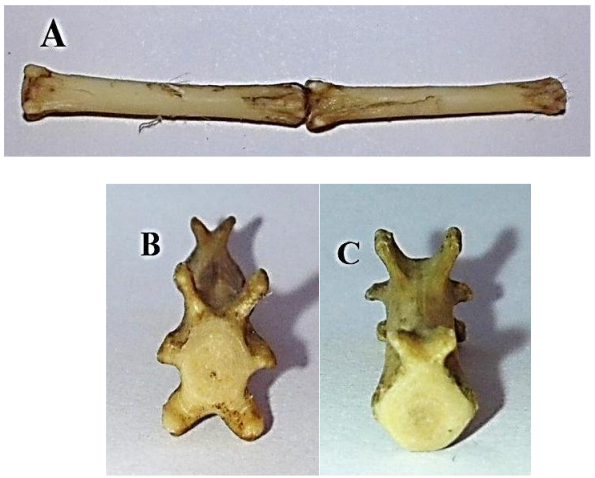


**Fig. 14.** Views of caudal vertebrae: A. Dorsal of the 14th and 15th vertebrae. B. Anterior- C. Posterior-10th vertebra.

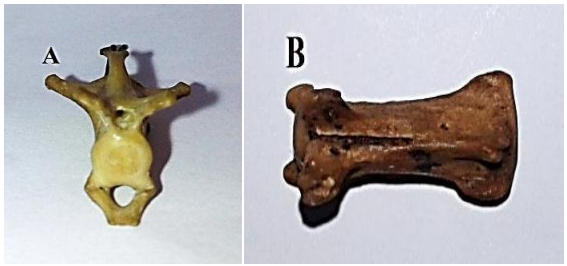


**Fig.15.** Views of caudal vertebrae: A. Anterior of the fourth vertebra. B. Dorsal of the seventh vertebra.

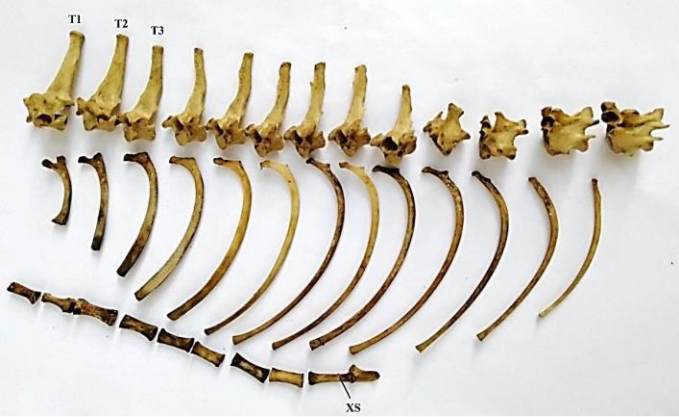


**Fig. 16.** Lateral view of thoracic cage.

**Fig. 17.** Lateral view of the 1st, 5th and 7th ribs.

## 4. Discussion

In foxes, the axial skeleton consists of the vertebrae of the vertebral column. Many different vertebral formulae have been reported in carnivores, including C7, T13-16, L4-6, S2-4, Ca15-25 in Mustelidae (Grasse, 1967); C7, T13, L7, S3, Ca- in the wolf and fox (Girgin *et al*., 1988); C7, T13, L7, S3, Ca- in the fox and jackal (Gultekin and Ucar, 1980).C7, T14, L6, S3, Ca- in the hyena (Tecirlioglu, 1983); C7, T14, L7, S3, Ca15-18 in the mink (Dursun and Tipirdamaz, 1989); C7, T14, L6, S3, Ca18 in otters (Yilmaz et al., 2000); C7, T13, L7, S2, Ca- in the domestic dog König and Liebich (2002) and Dyce *et al*. (2010) and C7, T13, L7, S2, Ca20-21 in the Crab-eating fox (Barisson *et al*., 2012). The results in *Vulpes ruppelli* specimens were: C7, T13, L7, S3, Ca22, which is nearly identical to the results in other foxes, wolves, and jackals.

Alar notch and transverse foramen were observed on the atlas of various animals such as the wolf and fox by Girgin et al., (1988); the hyena by Tecirlioglu, (1983); the jackal by Gultekin and Ucar (1980); and the otter by Yilmaz *et al*. (2000) and also in *Vulpes ruppelli* of this study.

The lumbar vertebrae of the crab-eating fox changed shape from anterior to posterior (Barisson *et al*., 2012). This latter view differs from the lumbar of the foxes in this study, which is increased from anterior to posterior. The Crab-eating fox's caudal vertebrae are fully developed in the anterior region, and the transverse processes of the first five caudal vertebrae are clearly visible (Barisson *et al*., 2012). This is similar to *Vulpes ruppelli*, except that the transverse processes are visible until the seventh caudal vertebra.

Dursun (1994), Evans and Christensen (1979), and Getty (1975) reported the presence of haemal arches in domestic dogs; ktay, (1988) reported the presence of haemal arches in carnivora and some rodentia; Dursun and Tipirdamaz, (1989) reported the presence of haemal arches in mink; Grasse (1967) reported the presence of haemal arches in wild squirrel. The haemal arches are missing in this study, but there is a triangular haemal foramen in the fourth and fifth caudal vertebrae.

In carnivora, ribs consist of nine sternal and four asternal ribs in the fox and jackal (Gultekin and Ucar, 1980); six sternal and seven asternal and one floating in the mink (Dursun and Tipirdamaz, 1989); nine sternal and four asternal and one floating in the dog (Evans and Christensen, 1979); nine sternal and two asternal and two floating in the otter crab-eating fox (Barisson *et al*., 2012; Yilmaz *et al*., 2000). According to the findings of this study, *Vulpes ruppelli* has nine sternal, three asternal, and one floating teeth.

Dursun and Tipirdamaz (1989) discovered that the body of the sternum in the mink has five sternebrae; the wolf and fox have eight (Girgin *et al*., 1988); the dog has eight or nine (Evans and Christensen, 1979); the crab-eating fox has eight (Barisson *et al*., 2012); and the otter has nine (Evans and Christensen, 1979; Yilmaz *et al*., 2000).

The sternum of *Vulpes ruppelli* is made up of nine sternebrae. The paddle-shaped process in the fourth normal cervical vertebra and the groove on the dorsal side of the seventh caudal vertebra, along with the triangular haemal foramen in the fourth and fifth caudal vertebrae, has not previously been reported.

## 5. Conclusion

The findings of this study fill a significant information gap in the axial skeleton of *V. rueppelli* fox that was previously unavailable. The components structures of vertebrae, sternum, and ribs that are involved in the thoracic cage of the mentioned fox have been demonstrated for the first time in this study. The other part of the axial skeleton that represents the morphology of the cranial components of the skull will be studied in the future. The appendicular skeleton, which leads to the completion of *V. rueppelli* fox's entire skeletal system, will also be covered in future papers.

## References

Barisson, J. D., Louro, C. H., Dias, S. J., Jojima, F. S., Ferreira, M. S., and Oliveira, F. S. (2012) 'Anatomo-radiographic description of the axial skeleton of the crab-eating fox (Cerdocyon thous)', *Pesquisa Veterinária Brasileira*, 32, pp. 01-03.

Dursun, N. (1994) 'Veteriner Anatomi I', *Medisan Yayinevi. Ankara*, pp. 73-110.

Dursun, N., and Tipirdamaz, N. (1989) 'Etudes macro anatomiquement sur les os du squelette du vison (Mustela vison)', *J. Fac. Vet. Med. Univ Selçuk*, 5, pp. 13-27.

Dyce K.M., Sack W.O. and Wensing C.J.G. (2010) Tratado de Anatomia Veterinária. Elsevier, Rio de Janeiro. 834p.

Ellerman, J., and Morrison-Scott, T. (1966) 'Checklist of Palaearctic and Indian Mammals 1758-1946. British Museum (Natural History).

Evans, H. E., and Christensen, G. C. (1979) 'Miller's Anatomy of the Dog. W.B. Saunders Comp.', *Philadelphia. pp*. 113-177.

Folkens, Tim, D. W. Michael, T. B. Pieter A. Pierter, Folkens; Michael, Black. (2012) Human Osteology (3rd). Amsterdam: Elsevier/Academic Press. p. 11. ISBN 978-0-12-374134-9.

Getty, R. (1975) 'Sisson and Grossman's the Anatomy of the Domestic Animals. W.B. Saunders Comp.', *Philadelphia*. pp. 1427-1482.

Girgin, A., Karadag, H., Bilgic, S., and Temizer, A. (1988) 'A study on the macro-anatomical differences of the skeletons of wolf and fox as compared with the skeleton of dog', *J. Fac. Vet. Med. Univ. Selçuk*. 4, pp. 169-182.

Grasse, P. P. (1967) Traité de Zoologie, Anatomie, Systématique, Biologie, Masson et Cie., Paris. pp. 593-632.

Gultekin, M., and Ucar, Y. (1980) 'Makro-anatomische Untersuchungen über die Unterschiede zwischen den einheimischen Hunden, Schakalen und Füchsen Teil-I. Truncus et Membra', *J. Fac. Vet. Med. Univ. Ankara*. 27, pp. 201-214.

Hüfnagl, E. (1972) Lybian mammals. The Olander Press, New York.

IUCN. (2006) Red list of threatened species. International Union for Conservation of Nature and Natural Resources, Gland, Switzerland.

König, H. E., and Liebich, H. G. (2002) Anatomia dos Animais Domésticos: aparelho locomotor. Porto Alegre: Art Med, 1, 291.

Öktay, M. (1988): Omurgali Hayvanlarin Karsilastirmali Anatomisi. Ist. Üniv. Fen. Fak. Basimevi, Istanbul.

Qumsiyeh, M. B. (1996) Mammals of the Holy Land. Texas Tech University Press.

Rosevear, D. R. (1974) The carnivores of West Africa. The British Museum (Natural History) London: publication number 723. ISBN 0565 00723 8.

Sillero-Zubiri, C., Hoffmann, M., and Macdonald, D. W. (2004) Status Survey and Conservation Action Plan—Canids: foxes, wolves, jackals and dogs. Gland, Cambridge (IUCN/SSC Canid Specialist Group).

Stephen, P., and Nawrocki, Ph.D., D.A.B.F.A. (1997) Clening bones. University of Indianapolis Archeology & Forensics Laboratory, Indianapolis, Indiana, U.S.

Tecirlioglu, S. (1983) 'Makro-Anatomische Untersuchungen über die Skelettkonchen von Hunden und der Hyäne. I: Truncus', *J. Fac. Vet. Med. Univ. Ankara*, 30, pp. 149-66.

Webster. (1974) Comparative Vertebrate Morphology. New York, and London. New York University, Academic Press.

Wozencraft, W. C. (2005) "Order Carnivora". In Wilson, D.E.; Reeder, D.M. Mammal Species of the World: A Taxonomic and Geographic Reference (3rd ed.). Johns Hopkins University Press. pp. 532–628. ISBN 978-0-8018-8221-0. OCLC 62265494.

Yilmaz, S., Dinç, G., and Toprak, B. (2000) Macro-anatomical investigations on skeletons of otter (Lutra lutra). III. Skeleton axiale. Department of Anatomy, Faculty of Veterinary Medicine, Firat University, Elazig, Turkey, 70 (4), 191-198