Libyan Journal of Science & Technology 14:1 (2022) 59-63

Faculty of Science - University of Benghazi

Libyan Journal of Science & Technology

journal home page: www.sc.uob.edu.ly/pages/page/77

Nephrotoxicity of Cyclophosphamide on Female Golden Hamster: Histopathological Study.

Rima A. Benomran [a], Maysoon F. Elrashdy [a], Nabeia A. Gheryani [b], Abeer H. Amer [a, *]

[a] *Department of Histology, Faculty of Medicine, University of Benghazi, Benghazi, Libya.*

[b] *Department of Pathology, Faculty of Medicine, University of Benghazi, Benghazi, Libya.*

Highlights

- **Histopathology is a good way to understand the underlying effects of drugs.**
- **Cyclophosphamide causes nephrotoxicity in the kidneys of female golden hamsters.**
- **The cyclophosphamide is dose-dependent.**
- **The most significant histological modification of the toxic dose of the cyclophosphamide was tubular necrosis and damage to renal glomeruli.**

ARTICLE INFO

Article history:

Received 26 May 2022
Revised 30 March 2022
Accepted 31 March 2022

Keywords:

Cyclophosphamide, Golden Hamsters, histopathology, nephrotoxicity.

**Address of correspondence:*

E-mail address: abeer.amer@uob.edu.ly

A. H. Amer

ABSTRACT

Cyclophosphamide is considered one of the most effective alkylating anticancer drugs used worldwide. But it is also acknowledged for its damaging side effects including nephrotoxicity, hepatotoxicity, immunotoxicity, and mutagenicity. This study was to investigate the histopathological changes induced by intraperitoneal injection of different doses of cyclophosphamide on the kidney tissue in female golden hamsters (*Mesocricetus auratus*). In this experimental study, 27 female golden hamsters were divided into three groups, control, therapeutic, and toxic dose groups. Animals in the control group were injected with normal saline, while those in the therapeutic, and toxic groups were injected with cyclophosphamide at doses of 100 and 200 mg/kg body weight respectively. The dosing was carried out on days 1, 3, and 5. Then on the seventh day, animals were humanely sacrificed. The kidney was maintained in formalin for histological examination. Histological examination of kidney tissue obtained from the animals treated with 100 mg/kg body weight cyclophosphamide (therapeutic dose) showed mild congestion in the glomerular capillaries and mild swelling of lining epithelial of some tubules. A significant histological alteration was observed at the toxic dose of 200 mg/kg body weight cyclophosphamide, were tubular necrosis and damage of renal glomeruli, this shows dose-dependent effects of the drug. The current study showed that the acute toxicity of renal tissue in female golden hamsters could be induced by the therapeutic or toxic doses of cyclophosphamide. Histopathological alterations were observed in the kidney tissue.

1. Introduction

The kidney is considered a vital organ that accomplishes many biological activities including the regulation of extracellular fluids amount and the excretion of metabolic waste products, acid-base balance, and electrolyte composition (Schnellmann, 2008). Drug-induced toxic effects on the kidney are common and an expected fact, and can disrupt the kidney tissue structure and functions (Choudhury and Ahmed, 2006). Cyclophosphamide is one of the most effective alkylating anticancer drugs, which are commonly used for the treatment of a number of cancers and autoimmune diseases (Sadeghi *et al*., 2017). Its harmful side effects include mutagenicity, hematotoxicity, immunotoxicity, lung and brain damage, and nephrotoxicity. Acrolein is the active metabolite of cyclophosphamide that is accountable for the toxic damaging side effects (Fraiser *et al*., 1991; Merwid-L *et al*., 2021). Cyclophosphamide-induced nephrotoxicity has been well recognized by researchers in both humans and animals (Joy and Nair, 2008). Nephrotoxicity due to cyclophosphamide can result in glomerular and tubular dysfunctions and a reduction in glomerular filtration rate (Sugumar *et al*., 2007). However, nephrotoxicity induced by cyclophosphamide is one of the main causes of severe morbidity in surviving cancer patients (Małyszko *et al*., 2017). Several studies have reported that cyclophosphamide may lead to toxicity to the urinary bladder (cystitis and bladder cancer) (Talar-Williams *et al*., 1996; Merwid-L *et al*., 2021), renal and liver damage (Nandini *et al*., 2018), brain and lung damage (Said *et al*., 2016; Zarei and Shivanandappa, 2016), and bone marrow suppression (Que *et al*., 2016), thereby limiting the therapeutic use of the drug. The histopathological signs of cyclophosphamide-induced renal damage include great hemorrhage in kidney tissue, swelling of tubules, tubular necrosis and fibrosis, reduction of Bowman's capsular space, and presence of inflammatory cell infiltrates, and atrophy of renal glomeruli (Kalantari *et al*., 2011; Merwid-L *et al*., 2021). In light of the above information, this study is to investigate the kidney damage caused by cyclophosphamide in female golden hamsters.

2. Material and Methods

Twenty-seven adult female golden hamsters (*Mesocricetus auratus*), were obtained from a farm in El-Bayda city, each weighing 150-250 grams. Hamsters were kept in plastic cages under pathogen-free standard conditions (24±4°C room temperature; 12-hour light/dark cycle), with *ad libitum* access to food and water throughout the experimental period. The experiment was conducted at the Histology Department, Faculty of Medicine, University of Benghazi-

© 2022 University of Benghazi. All rights reserved. ISSN: Online 2663-1407, Print 2663-1393; National Library of Libya, Legal number: 390/2018

Libya. Upon arrival, the animals were subjected to a quarantine period (10 days), staying in a collective cage of 2-3 individuals each. During this period, they were not subjected to any interventions. Cyclophosphamide was purchased as a powder from a local pharmacy, dissolved in normal saline at 37°C, and vigorously shaken. Other chemicals used were of the highest quality available. The animals were randomly divided into three groups, the control group, the therapeutic dose group (100 mg/kg body weight) (Tatiane *et al.,* 2009), and the toxic dose group (200 mg/kg body weight) (Tatiane *et al.,* 2009). The dosing was administrated by intraperitoneal injection, in a volume of 3-5 ml/kg on alternating days for one week, meaning they were dosed on days 1, 3, and 5. The kidneys were harvested on day 7 then sliced transversely and fixed in 10% neutral buffered formalin then processed by using the paraffin technique and made full-faced paraffin blocks (FFPB) of a kidney. The blocks were cut using a steal knife microtome and the sections were placed on clean glass slides that were stained with Hematoxylin and Eosin by deparaffinizing slides in 2 changes of xylene for 5 minutes each. Transfer slides to 100% alcohol, 2 changes for 3 minutes each, and transfer once through 95% alcohol for 3 minutes, hydrate to water. Then put in Mayer's hematoxylin for 15 minutes, wash in running tap water for 20 minutes to enhance the hematoxylin staining, and counterstain with eosin from 15 seconds to 2 minutes depending on the age of the eosin, and the depth of the counterstain desired. For even staining results dip slides several times before allowing them to set in the eosin for the desired time. Clear in xylene, two changes of 2 minutes each. Mount in DPX (distyrene, a plasticizer, and xylene) or Canada Balsam, and apply coverslip. The coverslip not only protects the tissue from damage but also is necessary for viewing the section with the microscope (Alashger *et al.,* 2021). Histopathological evaluation was carried out by a pathologist.

3. Results

Histological sections from the kidneys of the control group showed normal renal architecture of the cortex and medulla, with no inflammatory infiltrates and a normal Bowman's capsule. The collecting tubules, the loops of Henle, and the proximal and distal convoluted tubules had a normal structure as seen in Fig. 1. A and B. On the other hand, sections of the kidney tissue from the therapeutic group dosed with 100 mg/kg body weight cyclophosphamide showed mild congestion in the glomerular capillaries, while the epithelial cells in both the proximal and distal convoluted tubules were swelled. No inflammatory infiltrates were detected. The kidney cortex displayed mild congestion in the glomerular capillaries. The glomeruli were not shrunken and the capsular space was normal. Furthermore, rarefaction of the cytoplasm of the tubules could be found in addition to swollen cells of tubules and some pyknotic nuclei could be seen in some areas. Likewise, the renal medulla demonstrated rarefaction of the cytoplasm of the tubules, and pyknotic nucleus could be seen in some areas (Fig. 2A and B). In the toxic group (dosed with 200 mg/kg body weight cyclophosphamide), the changes were more severe compared to the therapeutic group, they were characterized by tubular necrosis and damage to renal glomeruli. The epithelial cells in both the proximal and distal convoluted tubules were swelled (or inflamed) with the loss of the brush border, and had numerous pyknotic nuclei. Some epithelial cell pieces were exfoliated in the tubular lumen. The glomeruli were atrophied and bowman's space became widened (Fig. 3). Furthermore, Fig. 4. A and B**,** presented occasional nucleus absence and swelling of tubules and tubular necrosis, marked blood vessel congestion, and an increase in thickness of their wall, in addition, Hemosiderin-laden macrophages were detected.

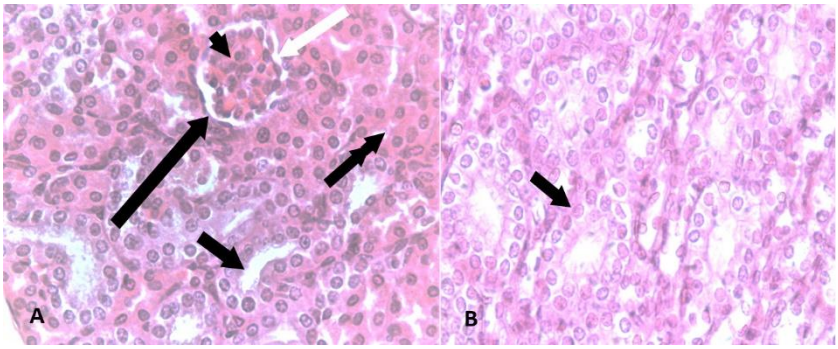

Fig. 1. Micrograph of the hamster kidney tissue from the control group showing the (A) Cortex showing: Rounded glomeruli (arrowhead), each glomerulus was surrounded by a narrow capsular space (white arrow) lined by flat squamous cells of the parietal layer (long arrow) of Bowman's capsule. The proximal convoluted tubules (double arrow) with a narrow lumen and rounded vesicular nuclei. The distal convoluted tubules (short arrow) are with the wide lumen and lined by simple cuboidal cells with rounded nuclei. (B) Medulla. showing numerous collecting ducts consisting of cuboidal cells resting on a basement membrane, with normal structure and rounded nuclei (black arrow). H and E stain, (X 400).

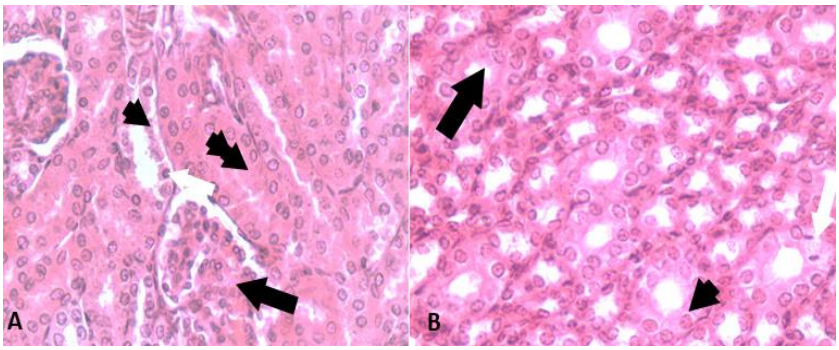

Fig. 2. Micrograph of the hamster kidney tissue from the therapeutic group showing the (A) cortex presenting: mild congestion in the glomerular capillaries (black arrow). Rarefaction of the cytoplasm of the tubules (arrowhead). Swollen cells of tubules (double arrow). The pyknotic nucleus could be seen in some areas (white arrow). (B) medulla. H and E stain, (X 400).

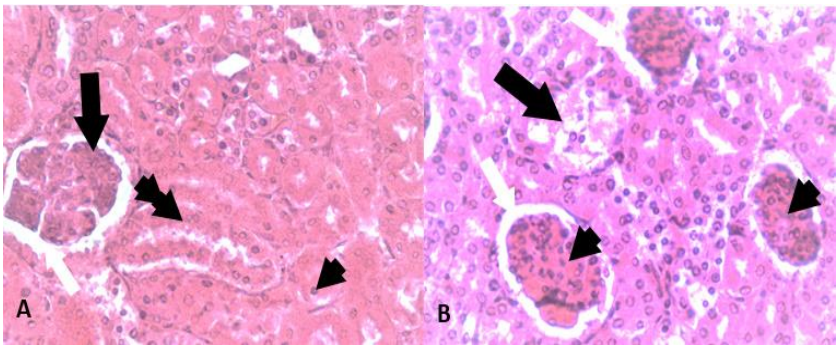

Fig. 3. Micrograph of the hamster kidney cortex tissue from the toxic group. (A) reveals swelling shrunken glomeruli (black arrow) with a wide capsular space (white arrow). The epithelial cells of the distal convoluted tubules were swelled (double arrow). Pyknotic nuclei increased in number are found (arrow head). (B) displays tubular necrosis (black arrow) and shrunken glomeruli (arrow head) with intra glomerular congestion and wide capsular space (white arrows). H and E stain, (X 400).

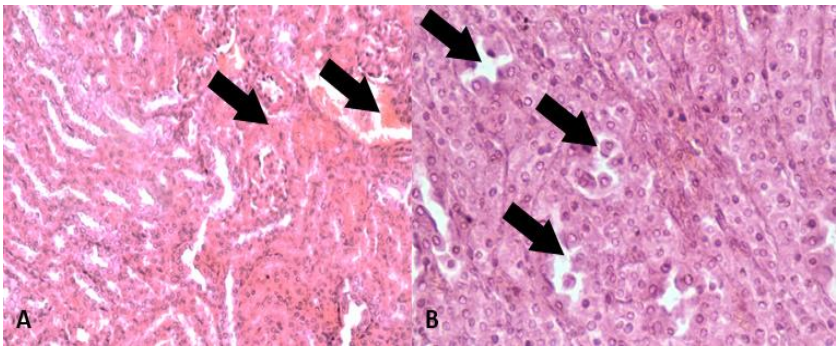

Fig. 4. Micrograph of the hamster kidney tissue from the toxic group. (A) cortex Blood vessels show marked congestion and an increase in thickness of their wall (black arrow). (B) medulla displaying tubular necrosis (black arrows), marked blood vessel congestion, and Hemosiderin-laden macrophages. H and E stain, (X 400).

4. Discussion

Cyclophosphamide is a chemotherapeutic agent that is used widely in the treatment of immunological diseases and malignancies, the cyclophosphamide is documented to stop cancer progression through cross-linking nucleobases in DNA, therefore harming the DNA, making it unable to uncoil, causing the cell to be incapable of replication (McDonald *et al.*, 2003). The precise mechanism by which cyclophosphamide induces renal injury is poorly known. However, studies have attributed it to its cytotoxic metabolite, the acrolein (Kern and Kehrer, 2002). Moreover, acute renal failure is a common and serious renal problem having great mortality and morbidity rate in most countries (Begum *et al.*, 2006). Histological examination of the kidney tissue is a valuable tool in evaluating drug-induced kidney damage (Kern and Kehrer, 2002). The histopathological signs of cyclophosphamide-induced renal pathology include tubular necrosis and fibrosis, hemorrhage, narrowing of Bowman's capsule space, atrophy of renal glomeruli, and presence of inflammatory cell infiltrates (Kalantari *et al.*, 2011). Additionally, the present study has investigated the histopathological changes that have occurred in the kidney of a group of hamsters that have received a therapeutic and toxic dose of cyclophosphamide. The results showed similar destruction of the histopathological structure of the kidney tissue to the literature (Merwid-L *et al.*, 2021). It is evident from the current results that cyclophosphamide administration induced many histological alterations in the kidney including congestion of renal blood vessels and degeneration of renal tubules as well as atrophy of the glomeruli, also showing the nephrotoxicity is clearly dose-dependent. In this study, the animals treated with the therapeutic nontoxic dose showed mild congestion in the glomerular capillaries of the cortex of the kidney, in comparison with the control group which showed normal histological structure, even though, the glomeruli and capsular space were normal in the nontoxic treated tissues. Additionally, the parietal layer (simple squamous epithelium) of the Bowman's capsule appeared also typical. On the other hand, the epithelial cells in both the proximal and distal convoluted tubules showed mild swelling and inflammation, with no inflammatory infiltrates detected, nevertheless the brush border showed a slight decrease in size. However, cytoplasm of the tubules had less density in addition to swollen cells of tubules and some pyknotic nuclei indicating the beginning of necrosis. This was in agreement with Cuce *et al.*, (2016) who reported in rat's significant tubular degeneration, glomerular inflammation, edema, and congestion but no necrosis. While in the medulla of the same dosed animals, rarefaction of cytoplasm of the tubules was similarly seen, and pyknotic nucleus also could be seen in some areas. These findings were in agreement with that announced by Dobrek *et al.*, 2017; Hamzeh *et al.*, 2018). Estakhri *et al.*, (2013) stated that one of the basic mechanisms involved in cyclophosphamide-induced nephrotoxicity could be oxidative stress. Others reported that rats treated with aqueous cyclophosphamide orally at a low dose level for four weeks, showed glomerular nephritis, interstitial edema, and cortical tubular vacuolization (Sakr and Abdel-Samie, 2016). Stating the difference in doses, duration, and animal type. In the current study, the findings in the hamsters treated with 200 mg/kg body weight cyclophosphamide (toxic dose) intraperitoneally were more severe and were characterized by tubular necrosis and further damage of renal glomeruli. The epithelial cells in both proximal and distal convoluted tubules were enlarged drastically, while some parts of the epithelial cell were exfoliated in the tubular lumen. Also, the epithelial cells of the distal convoluted tubules were swelled with a loss of brush border. As for the medulla it displayed blood vessels with marked congestion and an increase in thickness of their walls. Furthermore, the occasional absence of nuclei and swelling of tubules were indicated. Bowman's space was widened because of the shrunken glomeruli. Blood vessels show marked congestion and an increase in the thickness of their wall. Hemosiderin-laden macrophages were also detected. These findings are supported by other authors who found comparable results in rats and mice (Koss and Lavin, 1970; Hamzeh *et al.*, 2018; Cengiz, 2018), they also found glomerular atrophy and fragmentation. Furthermore, the tubular epithelial cells were inflamed with turbidity in their structure, epithelial cells fragment

in the tubules were present in the rats treated with a single dose of 200 mg/kg cyclophosphamide (Cengiz *et al.,* 2018). In our study we observed cyclophosphamide-induced kidney changes in a dose-dependent manner, this is come in agreement with Nandini *et al.,* (2018), as they found pathological changes such as infiltration of acute inflammatory cells in the cortex, odedma of tubular cells, loss of brush border and pyknotic cells. Although most experiments were inducted on rats or mice our study on hamsters explicates that the nephrotoxic effects are furthermore similar to other species. Similar changes were also suggested by Sakr and El-messady (2017) who observed dilation and congestion of renal blood vessels, vacuolations of epithelial lining renal tubules, and atrophy of glomerular tuft. Studies have demonstrated that oxidative stress could be a key mechanism in drug-induced renal toxicity as perceived by the escalation in the oxidative markers in the kidney tissues (Paget and Barnes, 1964). The histological changes therefore seen in the kidney tissues in this study caused by cyclophosphamide may also be attributed to the increase in oxidative stress. Authors reported that injury induced by cyclophosphamide administration may be due to overproduction of peroxynitrite and resultant deficiency of NO, which plays an important role in renal physiology. Their results reveal that enhanced nitrosative stress may play a role in cyclophosphamide-induced renal damage. cyclophosphamide-induced renal damage may be a consequence of nitric oxide deficiency and or overproduction of peroxynitrite (Abraham *et al.*, 2007). The nephrotoxicity of cyclophosphamide is generally overlooked because plasma creatinine (Cr), an indicator of the glomerular function of the kidney, is not altered significantly in patients on cyclophosphamide chemotherapy (Ghosh *et al.*, 1999). However, in recent studies, it is demonstrated that, in rat models, cyclophosphamide induces renal damage histologically (Alabi *et al.*, 2021), but the plasma Cr, a reliable biochemical marker of renal dysfunction, remains unaltered (Sugumar *et al.*, 2007). Studies showed that cyclophosphamide can be nephrotoxic, both in human and animal models. Research work has revealed that cyclophosphamide can result in glomerular and tubular dysfunctions in addition to glomerular and tubular proteinuria. Also, a reduction in glomerular filtration rate and a decrease in concentration function of a kidney has been reported in children on chemotherapy (Sugumar *et al.*, 2007; Ghosh *et al.*, 1999; Senthilkumar *et al.,* 2006).

In conclusion, the results of the present study indicated that the acute nephrotoxicity in female golden hamsters can be induced by cyclophosphamide, either with therapeutic or toxic doses, and pathological alterations were observed in the histology of kidney. Our study has demonstrated the effect of an increase in dosage of cyclophosphamide in female golden hamsters on pathological alterations observed in the histology of kidneys.

References

Abraham, P., Indirani, K., and Sugumar, E. (2007) 'Effect of cyclophosphamide treatment on selected lysosomal enzymes in the kidney of rats', *Explained Toxicology Pathology*, 59, pp.143-149.

Alabi, Q., Akomolafe, R., Omole, J., Aturamu, A., Ige, M., Kayode, O., Kajewole-Alabi, D. (2021) 'Polyphenol-rich extract of Ocimum gratissimum leaves prevented toxic effects of cyclophosphamide on the kidney function of Wistar rats', *BMC Complement Med Ther*., 21, pp. 274.

Alashger, A., Amer, A. and Benhasouna, A. (2021) 'Histopathological Study of Carcinoma Cervix through Reviewing of Female Genital Tract Cancer Cases of Pathology Archive, Benghazi University from (2002-2011)', *SJUOB*., 34(2), pp. 217 -225.

Begum, N.A., Dewan, Z.F., Nahar, N., & Mamun, M.I.R. (2006) 'Effect of n-Hexane extract of Nigella sativa on gentamicin induced nephrotoxicity in rats', *Bangladesh J. Pharmacol*., 1, pp.16-20.

Cengiz, M. (2018) 'Boric acid protects against cyclophosphamide-induced oxidative stress and renal damage in rats', *Cellular and Molecular Biology*, 64(12), pp.11-14.

Choudhury, D., Ahmed, Z. (2006) 'Drug-associated renal dysfunction and injury', *Nat. Clin. Pract. Neph*., 2(2), pp. 80-91.

Cuce, G., Esen, H. H., Koc, T., Canbaz, H. T., Limandal, C., Kalkan, S., and Gurbilek, M. (2016) 'Vitamin E partially ameliorates cyclophosphamide-induced nephrotoxicity in rats', *Progress in nutrition*, 18(2), pp. 140-145.

Dobrek, Ł., Skowron, B., Baranowska, A., Ciesielczyk, K., Kopańska, M., and Thor, P. (2017) 'Nephrotoxicity of a single dose of cyclophosphamide and ifosfamide in rats', *Acta Poloniae Pharmaceutica. Drug Research*, 74(5), pp. 1579-1589

Estakhri, R., Hajipour, B., Majidi, H., & Soleimani, H. (2013) 'Vitamin E ameliorates cyclophosphamide-induced nephrotoxicity', *Life Science, J;*10(6s) pp. 308-13.

Fraiser, L. H., Kanekal, S., Kehrer, J. P. (1991) 'Cyclophosphamide Toxicity characterizing and avoiding the problem', *Drugs*, 42(5) pp. 781-95. DOI: 10.2165/00003495-199142050-00005.

Ghosh, S., Ghosh, D., Chattopadhyay, S., and Debnath, J. (1999) 'Effect of ascorbic acid supplementation on liver and kidney toxicity in cyclophosphamide -treated female albino rats', *J. Toxicol. Science*, 24, pp. 141–144.

Hamzeh, M., Talebpour, A. F., Yaghubi, B. S., and Hosseinimehr, S. J. (2018) 'Nephroprotective effect of cerium oxide nanoparticles on cyclophosphamide-induced nephrotoxicity via anti-apoptotic and antioxidant properties in BALB/c mice', *Marmara Pharm J.*, 22 (2), pp. 180- 189.

Joy, J., and Nair, C. (2008) 'Amelioration of cisplatin-induced nephrotoxicity in Swiss albino mice by Rubia cordifolia extract', *J Can Res Ther*., 4(3), pp. 111-115.

Kalantari, H., Jalali, M., Jalali, A., Salimi, A., Alhalvachi, F., and Varga, B. (2011) 'Protective effect of Cassia fistula fruit extract on bromobenzene- induced nephrotoxicity in mice', *Hum Exp Toxicol.*, 30(10), pp. 1710-5.

Kern, J.C., and Kehrer, J.P. (2002) 'Acrolein-induced cell death: a caspase influenced decision between apoptosis and oncosis/necrosis', *Chem. Biol. Interact*., 139, pp. 79–95.

Koss, L.G., and Lavin, P. (1970) 'Effects of a Single dose of cyclophosphamide on various organs in the rat. II. Response of urinary bladder epithelium according to strain and sex', *J Natl Cancer Inst*., 44(5), pp. 1195-200.

Małyszko, J., Kozlowski, L., and Kozłowska, K., (2017) 'Cancer and the kidney: dangereoux liasons or price paid for the progress in medicine', *Oncotarget*., 8, pp. 66601-66619.

McDonald, G., Slattery, J., Bouvier, M., Red, S., Batchelder, A. L., and Kalhorn, T. F. (2003) 'Cyclophosphamide metabolism, liver toxicity, and mortality following hematopoietic stem cell transplantation', *Blood,* 101(5), pp. 2043 -2048.

Merwid-L, A.; Ziółkowski, P., Szandruk-Bender, M., Matuszewska, A., Szel, A., Trocha, M. (2021) 'Effect of a Low Dose of Carvedilol on Cyclophosphamide-Induced Urinary Toxicity in Rats', *A Comparison with Mesna. Pharmaceuticals*, 14, pp. 1237.

Nandini, B., Sneha, G. K., Supriya, P., and Vidya, M. (2018) 'Toxic Effects of different Doses of Cyclophosphamide on Liver and Kidney Tissue in Swiss Albino Mice: A Histopathological Study', *Ethiop J Science*, 28(6), pp. 711.

Paget, G. E., and Barnes, J. M. (1964) Toxicity Tests. In: Laurence, D.R., and Bacharach, A.L., Eds., Evaluation of Drug Activities, Academic Press, Massachusetts, pp. 1:135.

Que, L., He, L., and Yu, C. (2016) 'Activation of Nrf2-ARE signaling mitigates cyclophosphamide-induced myelosuppression', *Toxicol. Lett*., 262, pp. 17–26.

Sadeghi, A., Kalantar, M., Molavinia, S., Houshmand, G., Bahadoram, M., and Esmaeilizadeh, M., (2017) 'Ameliorative effects of hydroalcoholic extract of Lavandula officinalis L. on cyclophosphamide-induced nephrotoxicity in mice', *J Nephropathol.*, 6(4), pp. 324-332.

Said, E., Elkashef, W.F., and Abdelaziz, R. R. (2016) 'Tranilast ameliorates cyclophosphamide-induced lung injury and nephrotoxicity', *Can. J. Physiology Pharmacology*, 94, pp. 347–358.

Sakr, S. A., and Abdel-Samie, H. A. (2016) 'Effect of Ginko Biloba extract on cyclophosphamide-induced nephrotoxicity and oxidative stress in albino rats', *Canadian J. Pure Applied Science*, 10(2), pp. 3835-3845.

Sakr S., and El-messady, F. (2017) 'Cyclophosphamide Induced Histological and Immunohistochemical alterations in Kidney of Albino Rats: The Ameliorative Effect of Fennel Oil', *International Journal of Sciences*, 6(8), pp. 78-87.

Schnellmann, R.G. (2008) Toxic Responses of the Kidney.' Casarett and Doull's Toxicology, the basic science of poisons 1., 7th ed. New York: McGraw-Hill, pp. 583-7.

Senthilkumar, S., Devaki, T., Manohar, B. M., and Babu, M. S. (2006) 'Effect of squalene on cyclophosphamide-induced toxicity', *Clinical Chim. Acta.*, 364 pp. 335–342.

Sugumar, E., Kanakasabapathy, I., and Abraham, P. (2007) 'Normal plasma creatinine level despite histological evidence of damage and increased oxidative stress in the kidneys of cyclophosphamide treated rats', *Clin. Chim. Acta.*, 376, pp. 244–245.

Talar-Williams, C., Hijazi, Y. M., Walther, M. M., Linehan, W. M., Hallahan, C. W., and Lubensky, I. (1996) 'Cyclophosphamide-induced cystitis and bladder cancer in patients with Wegener granulomatosis', *Ann Intern Med.*, 124, pp. 477-484.

Tatiane Y., Nakamura K., Lucimara A., Natália A., and Maria. J. (2009) 'Toxic effects of different doses of cyclophosphamide on the reproductive parameters of male mice', *Brazilian Journal of Pharmaceutical Sciences*, 45(2), pp. 313-319.

Zarei, M., and Shivanandappa, T. (2016) 'Neuroprotective effect of Decalepis hamiltoni on cyclophosphamide-induced oxidative stress in the mouse brain', *J. Basic Clin. Physiol. Pharmacol.*, 27, pp. 341–348.