Libyan Journal of Science & Technology 15:2 (2025) 282-286

Faculty of Science - University of Benghazi

Libyan Journal of Science & Technology

journal home page: https://journals.uob.edu.ly/LJST

Clinical Profile and Surgical Outcomes of Hirschsprung's Disease in Benghazi: A Retrospective Study (2019-2024).

Lobna A. Elfrgani [a], Sumeia A. Ghannay [a], Ali I. Sati [a], Rodaina N. Alfarsi [b], Ghofran A. El-turbi [b], Aya A. Aloribe [b], Eslam M. Mahmoud [b], AlMotasem Billah I. Attiatallah [b]

[a] *Histology Department, Faculty of Medicine, University of Benghazi*

[b] *Department of Cytotechnology, Faculty of Biomedical Science, University of Benghazi*

Highlights

- **The paper proposes a unified framework to measure usability through four key dimensions—Effectiveness, Efficiency, Learnability, and Satisfaction—using specific mathematical formulas and standardized questionnaires.**
- **It addresses the common neglect of usability in software development by providing a structured, organized approach that transforms abstract quality metrics into practical, actionable data for developers.**
- **Validation through a case study on the "Al Wahda Mobile" service demonstrates the framework's simplicity and its potential for universal application across mobile, web, and desktop environments.**

ARTICLE INFO

Article history:

Received 03 November 2025
Revised 24 December 2025
Accepted 28 December 2025

Keywords:

Hirschsprung disease, congenital, aganglionosis, megacolon, enterocolitis, intestinal obstruction

* *Address of correspondence:*

Ali A. Sati

E-mail address: Ali.i.sati@uob.edu.ly

ABSTRACT

Hirschsprung's disease (HSD) is a congenital disorder of the enteric nervous system (ENS) due to defective migration of neural crest cells, resulting in a segment of the colon without ganglion cells which leads to functional obstruction of the intestines. The disease affects 1 in 5,000 live births, with males being more commonly affected. Surgical resection is often required for management, although 30-50% of patients may experience persistent symptoms. This study aims to evaluate the clinical presentation, diagnostic methods, extent of aganglionosis, and surgical outcomes of pediatric Hirschsprung's disease at Benghazi Children's Hospital (2019–2024), with particular focus on gender differences and complications such as Hirschsprung-associated enterocolitis. A retrospective study was carried out by reviewing the medical records of 116 patients who were diagnosed with Hirschsprung disease and came for follow-up to receive the designed treatment in the Pediatric Surgery Department at Benghazi Children's Hospital between 2019-2024. Of the 116 patients, 88 were males, and 28 were females, with a predominant age of 1-5 years old. Most of the patients had short-segment disease (75%) and were diagnosed with rectal biopsy (93%). Colostomy was performed as a temporary measure in most of the cases (72%), with reported complications of enterocolitis in 56%. This 5 years study suggests a higher incidence of HSD in Benghazi and the importance of increasing public awareness of the symptoms can promote early medical visits and early diagnosis in the neonatal period which may reduce the complexity of the disease and the need for multiple surgeries

1. Introduction

Hirschsprung's disease (HSD) is a congenital disorder of the enteric nervous system (ENS) due to incomplete migration of neural crest-derived neuroblast into the colon, causing the absence of ganglion cells in affected segments. This results in a functional intestinal obstruction, which leads to distension of the proximal colon.

The disease typically presents after birth with symptoms like delayed meconium passage and abdominal distension (Torroglosa *et al*., 2016), with 65% of cases diagnosed before 1 month of age and 95% before 1 year (Harrison *et al*., 1986). The disease is rare in adults, though some cases have been reported up to 74 years old (Menezes *et al*., 2006). Sibling studies show increased risk, particularly in cases of total colonic involvement (Bradnock et al., 2017). The disease affects 1 in 5,000 live births, with males being more commonly affected (Bradnock *et al*., 2017). Surgical resection is often required for management, although 30-50% of patients may experience persistent symptoms (Thakkar et al., 2017).

While most cases of Hirschsprung's disease are not familial, the condition is categorized as a neurocristopathy, with defects in genes such as RET, EDNRB, and GDNF contributing to the disease's development (Bolk *et al*., 2000; Amiel and Lyonnet, 2001). Mutations in the RET proto-oncogene are found in 35% of sporadic and 49% of familial cases (Löf Granström and Wester 2017; Stewart and von Allmen, 2003). Various other conditions, including Down syndrome and congenital anomalies, are also associated with HSD (Stewart and von Allmen, 2003).

Symptoms vary by age and severity. In neonates, delayed meconium passage, bilious vomiting, abdominal distension, and enterocolitis are common. In older children, chronic constipation, abdominal distension, and explosive stools may occur. In rare adult cases, long-standing constipation and abdominal discomfort were noted (Roorda *et al*., 2019; Trovalusci *et al*., 2025). Diagnosis of HSD is confirmed through a combination of clinical evaluation, imaging (contrast enema), and rectal biopsy. The transition zone between ganglionic and aganglionic bowel is often visible on imaging studies. However, rectal biopsy confirms the absence of ganglion cells, aiding in definitive diagnosis (Proctor *et al*., 2003; Kessmann, 2006, Trovalusci *et al*., 2025).

© 2025 University of Benghazi. All rights reserved. ISSN 2663-1407; National Library of Libya, Legal number: 390/2018

Surgical intervention is the primary treatment, often through a pull-through procedure (Lindert *et al.*, 2024), to remove the aganglionic segment. Newer techniques, such as single-stage trans-anal pull-through, have improved outcomes by reducing pain and hospitalization (Zhang *et al.*, 2022). Post-operative complications include enterocolitis, fecal incontinence, and residual constipation. Long-term care focuses on managing bowel function and preventing complications (Pakarinen and Mutanen, 2024). However, while surgical outcomes are generally positive, long-term challenges persist, including issues with bowel function, incontinence, and growth concerns in syndromic cases. Psychosocial impacts are significant, especially in children, affecting their quality of life (Hameed *et al.*, 2024).

This study aims to evaluate the clinical presentation, diagnostic methods, extent of aganglionosis, and surgical outcomes of pediatric Hirschsprung's disease at Benghazi Children's Hospital (2019–2024), with particular focus on gender differences and complications such as Hirschsprung-associated enterocolitis (HAEC).

2. Methods

2.1. Study Design: A retrospective study was conducted at the Department of Pediatric Surgery, Benghazi Children's Hospital, Libya. The study reviewed medical records of patients diagnosed with HSD who underwent surgical treatment and/or follow-up between October 2019 and November 2024.

2.2. Study Population: The study included all pediatric patients (aged <1 to 17 years) of both sexes diagnosed with any form of Hirschsprung's disease during the study period. Diagnosis was based on clinical presentation and confirmed by histopathological analysis of rectal biopsy specimens. Patients with incomplete medical records or uncertain diagnoses were excluded.

2.3. Data Collection: Patient data were collected retrospectively from archived medical records as following:

- Demographic data: age at diagnosis and sex.
- Clinical features: family history of HD and presenting symptoms including abdominal distension, vomiting, constipation, diarrhea, fever, and delayed passage of meconium.
- Diagnostic procedures: rectal biopsy findings and colonoscopic assessment to determine the extent of aganglionosis (classified as short-segment or long-segment HSD)
- Surgical interventions and complications: type of surgical procedure performed, including colostomy, pull-through surgery, and/or colon dilation

2.4. Statistical Analysis: Data were entered and processed using Microsoft Excel (version 2010). Descriptive statistics were used to summarize patient characteristics, clinical features, and surgical interventions. Categorical variables were analyzed using the Chi-square test to assess associations between clinical variables, including gender and postoperative complications. A p-value < 0.05 was considered statistically significant.

2.5. Ethical approval: This study was conducted in accordance with the ethical principles outlined in the Declaration of Helsinki. Ethical approval was obtained from the Institutional Review Committee of Benghazi Children's Hospital prior to data collection. Patient confidentiality was strictly maintained throughout the study, and all data were anonymized before analysis.

3. Results

3.1. Age Group and Gender Distribution: A total of 116 cases of HSD were identified between October 2019 and November 2024. Patient ages at the time of diagnosis ranged from infancy to 17 years, with the pre-school age group (1-5 years) being the predominant age group (Fig. 1). Of the 116 patients, 88 (76%) were male and 28 (24%) were female, yielding a male-to-female ratio of approximately 3:1 (Fig. 2).

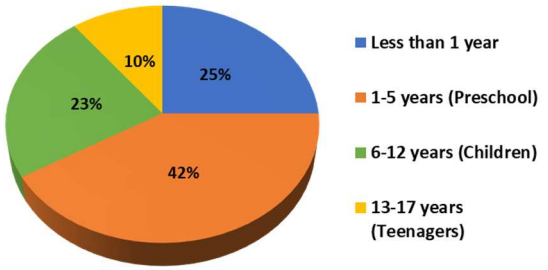

Fig. 1. Age Distribution of Patients with Hirschsprung's Disease.

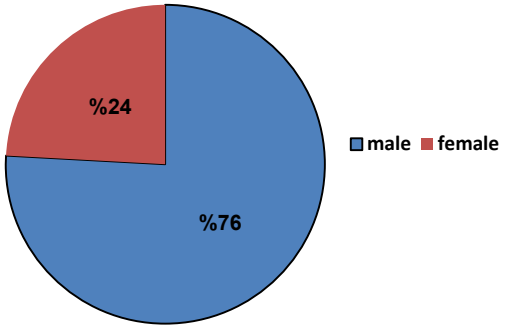

Fig. 2. Gender Distribution of Hirschsprung's Disease Cases

3.2. Annual distribution of diagnosed cases: The annual distribution of newly diagnosed HSD cases varied over the study period. Data showed that the lowest number of cases was recorded in 2019 (9 cases, 7.8%), while the highest number was in 2020 (27 cases, 23%). This was followed by a gradual decline in the number of cases in the subsequent years. As of November 2024, 12 new cases had been diagnosed, which was about 10% of the total cases (Fig. 3).

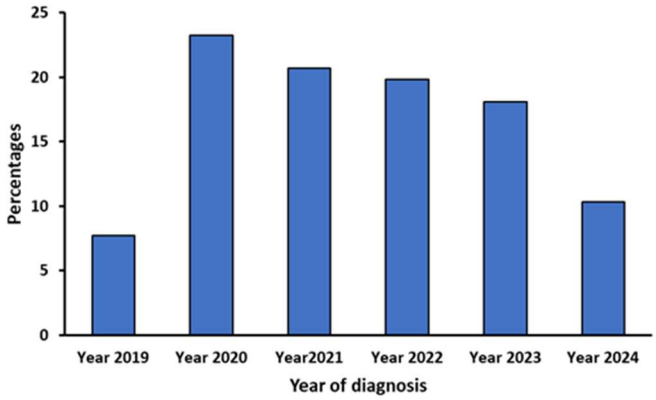

Fig. 3: Proportions of Hirschsprung's disease cases diagnosed annually from 2019 to 2024

3.3. Family History: A positive family history of HSD was reported in 13 patients (11%), while the remaining103 cases (89%) had no known familial predisposition (Fig. 4).

3.4. Clinical presentation: Abdominal distension was the most frequent symptom in HSD patients, which was reported in 30%. This was followed by vomiting, constipation, and diarrhea (18%, 21%, and 10%, respectively). Delayed passage of meconium a hallmark neonatal sign of HSD was documented in only 6% of cases (Fig. 5).

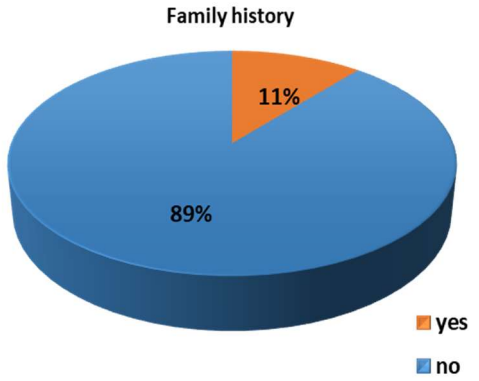

Fig. 4: Prevalence of positive family history of Hirschsprung's disease

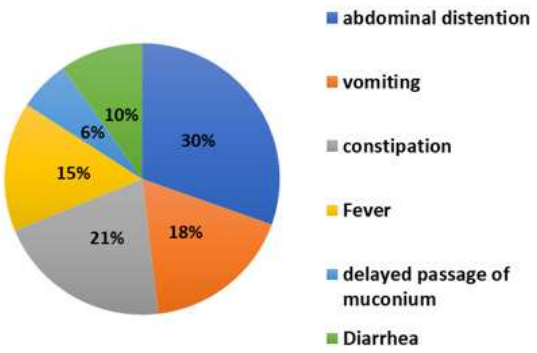

Fig. 5: Frequency of Symptoms in Hirschsprung's Disease Patients

3.5. Diagnostic Evaluation: Rectal biopsy was performed in 108 patients (93%) to confirm the diagnosis of HSD. In the remaining 8 cases (7%), no biopsy was documented in the medical records. Based on histopathological findings, short-segment aganglionosis was the most common subtype, observed in 87 patients (75%). Long-segment aganglionosis was identified in 29 patients (25%) (Fig. 6). No cases of total colonic aganglionosis were reported. A Chi-square test revealed no significant association between gender and the type of aganglionosis (Table 1), both have similar distribution with no significant difference ($p > 0.05$).

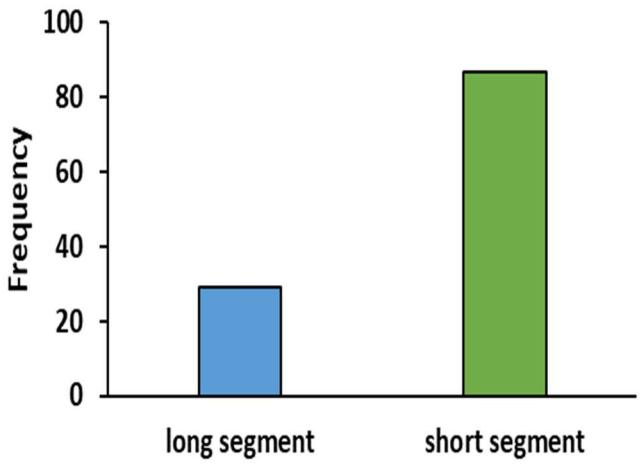

Fig. 6. Distribution of aganglionosis extent among Hirschsprung's disease patients

Table 1

The distribution of short-segment versus long-segment aganglionosis by gender. No statistically significant association was observed between gender and the type of aganglionosis,

		Extent of aganlionosis		
		Short segment aganglionosis	Long segment aganglionosis	Total
Gender	Male	66 (75%)	22 (25%)	88
	Female	21 (75%)	7 (25%)	28
Total		87	29	116

3.6. Surgical Management: Colostomy was performed as a temporary surgical intervention in 84 patients (72%), typically as part of a staged approach to definitive surgery. In contrast, 32 patients (28%) did not undergo colostomy, either due to direct definitive surgery or lack of documentation.

Pull-through surgery, the standard definitive procedure for HSD, was performed in 51 patients (44%). However, surgical records did not specify the exact technique used (e.g., Swenson, Soave, or Duhamel) in many cases. Additionally, colon dilation was performed in 24 patients (21%) as part of their surgical or preoperative management (Fig. 7).

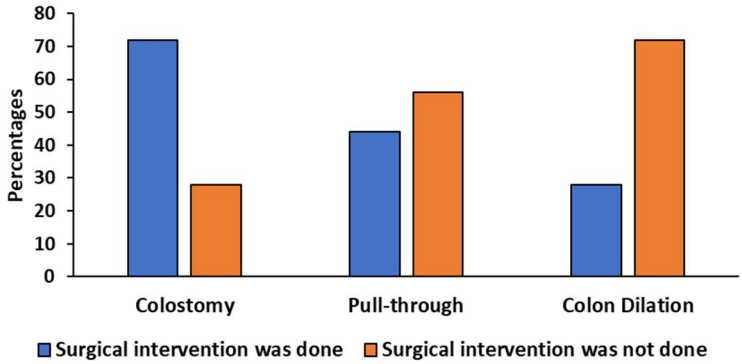

Fig. 7. The proportions of the use of colostomy, pull-through surgery and colon dilation in the management of patients with Hirschsprung's disease

3.7. Complications: Hirschsprung-associated enterocolitis (HAEC) was the most frequently documented postoperative complication, affecting 65 patients (56%) (Figure 8). A Chi-square test revealed a statistically significant association between gender and the occurrence of enterocolitis, with 62.5% of male patients developing enterocolitis compared to 35.7% of female patients (Table 2) ($^{**}p < 0.05$). Mortality was reported in 5 patients (4%), with causes including complications of enterocolitis, circulatory collapse, and chronic intestinal inflammation.

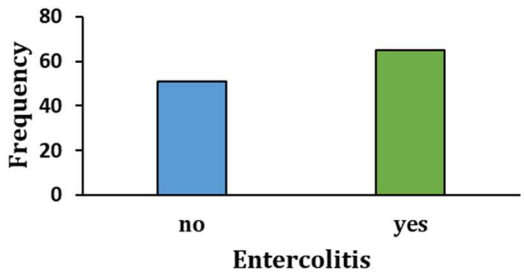

Fig. 8. Frequency of enterocolitis as a complication in Hirschsprung's disease patients

Table 2

The association between gender and the occurrence of enterocolitis. The Chi-square test revealed a statistically significant difference between genders (**p < 0.05)

		Occurrence of enterocolitis		
		Yes	No	Total
Gender	Male	55 (62.5%) **	33 (37.5%)	88
	Female	10 (35.7%)	18 (64.3%)	28
Total		65	51	116

4. Discussion

Hirschsprung's disease is a congenital disorder characterized by the absence of the enteric nervous system (ENS) in the distal bowel, resulting in functional intestinal obstruction. As the ENS regulates essential bowel functions, even a short segment of aganglionosis can lead to serious complications, including enterocolitis, perforation and death in some cases, in delayed treatment. Early diagnosis and timely surgical intervention are critical in reducing morbidity and improving long-term outcomes.

This study aimed to identify the clinical profile and assess the problem of HSD in Benghazi, Libya over a five-year period and used the data from medical records to ensure accurate case ascertainment. A total of 116 patients were identified, with a male-to-female ratio of approximately 3:1, which is consistent with previously reported male predominance in HSD (Bhatnagar, 2013; Torroglosa *et al.*, 2016). However, this ratio was slightly higher than that reported in Egypt (2:1) (Gad *et al.*, 2010) and Iran (2:1) (Izadi *et al.*, 2007). The age distribution in our cohort further highlighted a delay in diagnosis: only 25% of patients were diagnosed during the neonatal period, in contrast to studies in high-resource settings where up to 90% of cases are detected within the first month of life (Pratap *et al.*, 2007). This delayed presentation may reflect limitations in early diagnostic capacity, lack of disease awareness, or socioeconomic barriers to accessing specialized pediatric surgical care.

The majority of cases in this study were sporadic (89%), with 11% reporting a positive family history. These findings align with previous studies showing that most HSD cases are non-familial, though genetic transmission is well-documented in certain subsets (Löf Granström and Wester, 2017). The RET proto-oncogene is the most commonly implicated gene, found in approximately 35% of sporadic and up to 49% of familial cases (Löf Granström and Wester, 2017). The inheritance pattern is complex, with incomplete penetrance and sex-dependent expression.

The most frequently observed symptom in our cohort was abdominal distension (30%), followed by constipation (21%) and vomiting. Interestingly, delayed passage of meconium, a classical neonatal indicator of HSD—was documented in only 6% of cases. This is lower than expected and may again point to delays in recognizing early signs or incomplete documentation in neonatal records. Comparisons with other studies show varying symptom patterns: Arshad *et al.* (2012) reported 50% constipation and 87% abdominal distension in their cohort, while Howsawi *et al.* found that bilious vomiting and abdominal distension were the most frequent symptoms, each observed in over 60% of cases (Howsawi *et al.*, 2019). Bradnock *et al.* (2017) further emphasized that only a minority of HSD patients present with the classic triad of delayed meconium, abdominal distension, and bilious vomiting, underlining the variability in presentation and the potential for misdiagnosis or delayed referral (Bradnock *et al.*, 2017).

Rectal biopsy was the standard for confirming the diagnosis of HSD and was performed in 93% of patients. Histopathological analysis revealed that 75% of cases had short-segment aganglionosis and 25% had long-segment disease, while no cases of total colonic aganglionosis were observed. These proportions are comparable to other studies estimates where short-segment disease predominates (Yulianda *et al.*, 2019).

Colostomy is often recommended before pull-through in cases with severe enterocolitis, megacolon, or perforation. The stoma is usually temporary, and once the bowel heals, the healthy intestine is reconnected to the anus (Neuvonen *et al.*, 2017; Smith *et al.*, 2020). Our results showed that 72% of the cases underwent colostomy and 44% had a pull-through procedure, which is the definitive treatment for HSD involving resection of aganglionic segment and restoring bowel continuity with normally innervated intestine (Kessmann, 2006; Lindert *et al.*, 2024). Colon dilation was performed in 21% of patients, likely as part of preoperative decompression or palliative management.

Hirschsprung-associated enterocolitis (HAEC) remains one of the most serious complications, and it was observed in 56% of patients. This is on the higher end of the global spectrum, where rates typically range from 20% to 50% (Smith *et al.*, 2020). The high incidence in our cohort could be related to delayed diagnosis (Trovalusci *et al.*, 2025), extensive aganglionosis, or limited access to specialized postoperative care. HAEC is thought to result from a combination of fecal stasis, altered intestinal microbiota, and mucosal immune dysregulation. Its incidence generally declines over time as mucosal immunity matures (Hagens *et al.*, 2022).

A statistically significant gender difference was identified in our cohort: 62.5% of male patients developed enterocolitis compared to 35.7% of females. This finding supports previous studies, such as that by Yulianda *et al.* (2019), which also reported higher HAEC incidence among males. Mortality in our cohort was 4%, with causes including severe HAEC, circulatory collapse, and chronic intestinal inflammation. Although relatively low, these deaths highlight the potential severity of untreated or poorly managed HSD complications.

5. Epidemiological Implications

While this study did not establish a definitive prevalence rate due to the absence of live birth data for Benghazi, the identification of 116 cases over five years suggests a substantial disease burden. For comparison, a 25-year study conducted in Boston identified 179 cases, equating to approximately 6–7 cases per year (Ryan *et al.*, 1992). Our findings suggest a potentially higher incidence in Benghazi, which may reflect genetic clustering, regional population characteristics, or improved diagnostic capture in recent years. However, definitive conclusions require population-based studies and better national reporting systems.

6. Conclusion

This study provides valuable insights into the clinical profile and management of Hirschsprung's disease in Benghazi. The high number of cases, delayed diagnosis, and elevated rate of postoperative enterocolitis underscore the need for improved early detection and standardized treatment protocols. Greater public and professional awareness, particularly regarding atypical or late presentations, may aid in reducing diagnostic delays and complications.

References

Amiel J., & Lyonnet S. (2001) 'Hirschsprung disease, associated syndromes, and genetics: a review', *Journal of Medical Genetics*, 38 (11), pp. 729-739.

Arshad, A., Powell, C., Tighe, M.P. (2012) 'Hirschsprung's disease', BMJ, 345(oct01 2), e5521–e5521.

Bhatnagar S.N. (2013) 'Hirschsprung's Disease in Newborns', *Journal of neonatal surgery*, *2*(4), p. 51.

Bolk, S., Pelet, A., Hofstra, R. M., Angrist, M., Salomon, R., Croaker, D., Buys, C. H., Lyonnet, S., & Chakravarti, A. (2000). A human model for multigenic inheritance: phenotypic expression in Hirschsprung disease requires both the RET gene and a new 9q31 locus. *Proceedings of the National Academy of Sciences of the United States of America*, *97*(1), 268–273.

Bradnock, T.J., Knight, M., Kenny, S., Nair, M., Walker, G.M. (2017) 'Hirschsprung's disease in the UK and Ireland: Incidence and

anomalies.', *Archives of Disease in Childhood*, 102(8), pp. 722–727.

Gad El-Hak, N.A., El-Hemaly, M.M., Negm, E.H., El-Hanafy, E.A., Abdel Messeh, M.H., Abdel Bary, H.H. (2010) 'Functional outcome after Swenson's operation for Hirshsprung's disease', *Saudi journal of gastroenterology*: official journal of the Saudi Gastroenterology, 16(1), pp. 30–34.

Hagens, J., Reinshagen, K., Tomuschat, C. (2022) 'Prevalence of Hirschsprung-associated enterocolitis in patients with Hirschsprung disease', *Pediatric Surgery International*, 38(1), pp. 3-57.

Hameed, R.A., Hoel, A. T., Diseth, T.H. (2024) 'Adolescent outcomes and quality of life in Hirschsprung's disease', *Journal of Pediatric Surgery*, 59, pp. 1037–1043.

Harrison, M.W., Deitz, D.M., Campbell, J.R., Campbell, T.J. (1986) 'Diagnosis and management of Hirschsprung's disease. A 25-year perspective', *American journal of surgery*, 152(1), pp. 49–56.

Howsawi, A., Bamefleh, H., Al Jadaan, S., Crankson, S., Alkhilaiwi, R., Al-Essa, R., Aljahdali, F., Al Nemari, J., Al Aqeely, K., Al Howti, S., Al Juhaiman, M., Bin Dajim, N. (2019) 'Clinicopathological Characteristics of Hirschsprung's Disease with Emphasis on Diagnosis and Management: A Single-Center Study in the Kingdom of Saudi Arabia', *Global pediatric health*, 6, 2333794X19848865.

Izadi M., Fariborz M., Jafarshad R., Farahnaz J., Bagherzadeh AH, Tareh F. (2007) 'Clinical manifestations of Hirschsprung's disease: A 6-year course review on admitted patients in Guilan, north Province of Iran', *International Cardiovascular Research Journal*, 1(1), pp. 25-31.

Kessmann J. (2006) Hirschsprung's disease: diagnosis and management. *American family physician,* 74(8), 1319-132.

Lindert, J., Schulze, F., Märzheuser, S.B. (2024) 'Bowel management in Hirschsprung disease—Pre-, peri- and postoperative care for primary pull-through', *Children*, 11(5), p. 588.

Löf Granström, A., Wester, T. (2017) 'Mortality in Swedish patients with Hirschsprung disease', *Pediatric Surgery International*, 33(11), pp. 1177–1181.

Menezes, M., Corbally, M., Puri, P. (2006) Long-term results of bowel function after treatment for Hirschsprung's disease: a 29-year review. *Pediatric surgery international*, *22*(12), pp. 987–990.

Neuvonen, M.I., Kyrklund, K., Rintala, R.J., Pakarinen, M.P. (2017) 'Bowel Function and Quality of Life After Transanal Endorectal Pull-through for Hirschsprung Disease: Controlled Outcomes up to Adulthood', *Annals of Surgery*, 265(3), pp. 622-629.

Pakarinen, M.P., Mutanen, A. (2024) 'Long-term outcomes and quality of life in patients with Hirschsprung disease', *World Journal of Pediatric Surgery*, 7(3), e000859.

Pratap, A., Gupta, D.K., Tiwari, A., Sinha, A.K., Bhatta, N., Singh, S.N., Agrawal, C.S., Kumar, A., Adhikary, S. (2007) 'Application of a plain abdominal radiograph transition zone (PARTZ) in Hirschsprung's disease', *BMC Paediatrics*, 7(5), https://pubmed.ncbi.nlm.nih.gov/17257439

Proctor, M.L., Traubici, J., Langer, J.C., Gibbs, D.L., Ein S.H., Daneman, A., Kim, P.C. (2003) 'Correlation between radiographic transition zone and level of aganglionosis in Hirschsprung's disease: implications for surgical approach', *Surgery*, 38(5), pp. 775-778.

Ryan, E.T., Ecker, J.L., Christakis, N.A., Folkman, J. (1992) 'Hirschsprung's disease: associated abnormalities and demography', *Journal of pediatric surgery*, 27(1), pp. 76–81.

Roorda, D., Surridge, T.J., Visschers, Rubin, G.J. Visschers, Derikx, J.P.M., van Heurn, L.W.E. (2019) 'Redo surgery with longitudinal resection for dilated bowel in Hirschsprung disease: an illustrative case series', *International Journal of Colorectal Disease*, 34(11), pp. 1983–1987.

Smith, C., Ambartsumyan, L., Kapur, R.P. (2020) 'Surgery, Surgical Pathology, and Postoperative Management of Patients with Hirschsprung Disease', *Pediatric and Developmental Pathology*, 23(1), pp. 23-39.

Stewart, D.R., von Allmen, D. (2003) 'The genetics of Hirschsprung disease', *Gastroenterology clinics of North America*, *32*(3), p. 819–vi.

Thakkar, H.S., Bassett, C., Hsu, A., Manuele, R., Kufeji, D., Richards, C.A., Agrawal, M., Keshtgar, A.S. (2017) 'Functional outcomes in Hirschsprung disease: A single institution's 12-year experience', *Journal of Pediatric Surgery*, *52*(2), pp. 277–280.

Torroglosa, A., Alves, M.M., Fernández, R.M., Antiñolo, G., Hofstra, R.M., Borrego, S. (2016) 'Epigenetics in ENS development and Hirschsprung disease', *Developmental biology*, 417(2), pp. 209–216.

Trovalusci, E., Thelele, T., Midrio, P., Bebington, C., Westgarth-Taylor, C., Brisighelli, G. (2025) 'The burden of delayed diagnosis in Hirschsprung disease: Insights from a paediatric colorectal centre in South Africa', *BMC Paediatrics*, 25, p. 547.

Yulianda, D., Sati, A.I., Makhmudi, A., Gunadi, null. (2019) 'Risk factors of preoperative Hirschsprung-associated enterocolitis', *BMC Proceedings*, 13(Supply 11), p. 18.

Zhang, Y., Liu, Z., Li, S., Yang, S., Zhao, J., Yang, T., Li, S., Chen, Y., Guo, W., Hou, D., Li, Y., & Huang, J. (2022) 'One-stage transanal endorectal pull-through for Hirschsprung disease: experience with 229 neonates', *Pediatric surgery international*, 38(11), pp. 1533–1540.